

# Reading Material for Dental Hygiene – II



**Compiled By:**

**Punjab Medical Faculty**

**Specialized Healthcare & Medical Education Department**

**Government of the Punjab**

## **Table of Contents**

### **Chapter: 1**

#### **Pathology and Microbiology**

Inflammation in Dental Tissues .....	4
--------------------------------------	---

### **Chapter: 2**

#### **Cariology**

Dental Caries .....	8
Etiology of dental caries .....	12
Classification .....	14
Types of Caries .....	16
Management of Caries .....	16

### **Chapter: 3**

#### **Periodontology**

Overview .....	17
Healthy Periodontium .....	17
Histology .....	19
History and Clinical Examination .....	21
Dental History .....	24
Social History .....	25
Medical History .....	25
Clinical Examination .....	26
Basic Periodontal Examination (BPE) .....	28

### **Chapter: 4**

#### **Dental materials**

What is Dental Materials .....	34
--------------------------------	----

Classification of Dental Materials .....	35
Properties of Dental Materials .....	37
<b>Chapter: 5</b>	
<b>Orthodontics</b>	
Types of dentition .....	43
Classification of Malocclusion .....	45
<b>Orthodontic Appliances</b>	
Removable appliances .....	50
Fixed Appliances .....	55
Functional Appliances .....	57
Common Instruments used in Orthodontics .....	59
<b>Chapter: 6</b>	
<b>Local Anesthesia</b>	
Common local anesthetic solutions .....	61
Ideal properties of Local Anesthetic agents .....	61
Types of Local Anesthesia .....	62
Composition of Local Anesthetich solution .....	63
Equipment required for Local Anesthesia .....	64
Infiltration Nerve Block .....	64
Complications of Local Anesthesia .....	68
<b>Sample Questions</b> .....	69
<b>REFERENCES</b> .....	70

## **PREFACE**

A two year post matric teaching program of Dental Hygiene for the students of Dental Hygienist. The purpose of this reading material is to provide basic education to the paramedics that fall in the domain of Dental hygienists. This reading material attempts to cover the basic theoretical knowledge required by the student about Dental Hygiene and procedures so that they can be performed under supervision in Dental Hospitals and Clinics.

## **Chapter: 1**

### **Pathology and Microbiology**

#### **1.1. Inflammation mechanism in dental tissues**

The macroscopic and microscopic anatomy of the oral cavity is complex and unique in the human body. Soft-tissue structures are in close interaction with mineralized bone, but also dentine, cementum and enamel of the teeth. These are exposed to intense mechanical and chemical stress as well as to dense microbiologic colonization.

Teeth are susceptible to damage, most commonly to caries, where microorganisms from the oral cavity degrade the mineralized tissues of enamel and dentine and invade the soft connective tissue at the core, the dental pulp. However, the pulp is well-equipped to sense and fend off bacteria and their products and mounts various and intricate defense mechanisms. The front rank is formed by a layer of odontoblasts, which line the pulp chamber towards the dentine. These highly specialized cells not only form mineralized tissue but exert important functions as barrier cells. They recognize pathogens early in the process, secrete antibacterial compounds and neutralize bacterial toxins, initiate the immune response and alert other key players of the host defense.

As bacteria get closer to the pulp, additional cell types of the pulp, including fibroblasts, stem and immune cells, but also vascular and neuronal networks, contribute with a variety of distinct defense mechanisms, and inflammatory response mechanisms are critical for tissue homeostasis. Still, without therapeutic intervention, a deep carious lesion may lead to tissue necrosis, which allows bacteria to populate the root canal system and invade the periradicular bone via the apical foramen at the root tip. The periodontal tissues and alveolar bone react to the insult with an inflammatory response, most commonly by the formation of an apical granuloma. Healing can occur after pathogen removal, which is achieved by disinfection and obturation of the pulp space by root canal treatment.

This review highlights the various mechanisms of pathogen recognition and defense of dental pulp cells and periradicular tissues, explains the different cell types involved in the immune response and discusses the mechanisms of healing and repair, pointing out the close links between inflammation and regeneration as well as between inflammation and potential malignant transformation.

#### **Common Oral Pathologies**

Oral and maxillofacial pathology is a dentistry specialization that diagnoses, studies and treats various oral diseases.

## **Soft tissue lesions**

Soft tissue lesions are one category of oral disease. The soft tissues of the mouth include the tongue, gums, cheeks and lips. Soft tissue lesions appear as ulcers, red or white patches, or small bumps, and can be caused by a variety of different factors.

One example of a condition that affects the soft tissues of the mouth is **leukoplakia**, a painless white patch that develops in the mouth. Leukoplakia can be precancerous, so it is important to get it checked and treated by a specialist.

## **Bone lesions**

Bone lesions are another type of oral pathology. They are generally divided into two categories: tumors and dental cysts. Bone lesions are most often detected using 3D x-ray. They can have significant health consequences, so they should be treated promptly once discovered.

## **Oral cancer (Squamous cell carcinoma)**

Squamous cell carcinoma affects a significant number of people in Quebec. Almost 700 Quebecers are diagnosed with oral cancer every year, and nearly 300 die from it. People who smoke, drink alcohol or do both are most at risk for oral cancer.

Here are a few symptoms that may indicate oral cancer:

- An ulcer that refuses to heal
- Swollen lymph nodes under the jaw and in the neck
- A hard gingival mass

## **Infections in and around oral cavity**

Some infections are common from childhood to adulthood listed below;

- Dental caries
- Gingivitis
- Periodontal disease
- Thrush
- Aphthous ulcer
- Oral herpes
- Herpangina

## **Acute inflammation**

- Acute inflammation is an immediate, adaptive response with limited specificity caused by several noxious stimuli, such as infection and tissue damage (tissue necrosis).

## **1.2. Immunity**

- Immunity is the “ability of the body to defend itself against disease-causing organisms.”

Everyday our body comes in contact with several pathogens, however, only a few results into diseases. The reason is, our body has the ability to release antibodies against these pathogens and protects the body against diseases.

## Chapter: 2

### CARIOLOGY

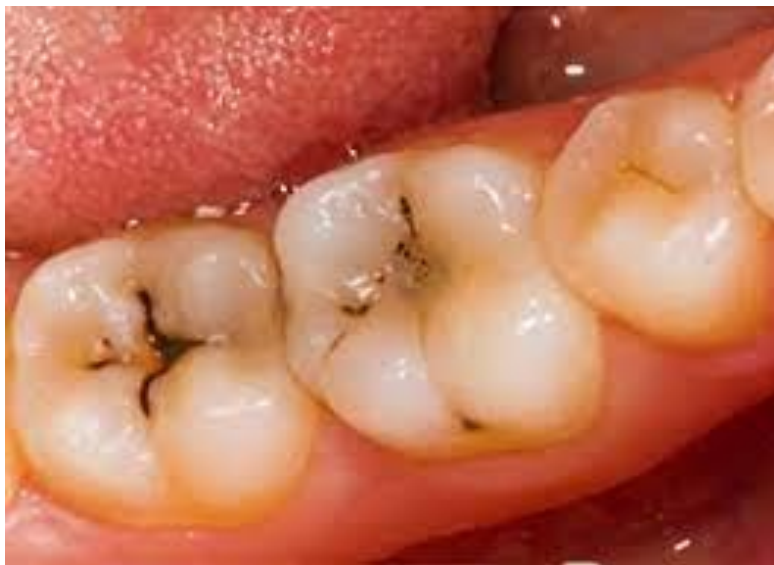#### Objective:

To build understanding regarding etiology, types, classification and treatment of Dental caries.

#### 2.1. DENTAL CARIES

##### Definition

- Dental caries is defined as a microbiological disease of the hard structure of teeth, which results in localized demineralization of the inorganic portion and destruction of the organic substances of the tooth.
- Cariology is a science which deals with the study of etiology, histopathology, epidemiology, diagnosis, prevention and treatment of dental caries.



**Figure:** Dental Caries



## Etiology

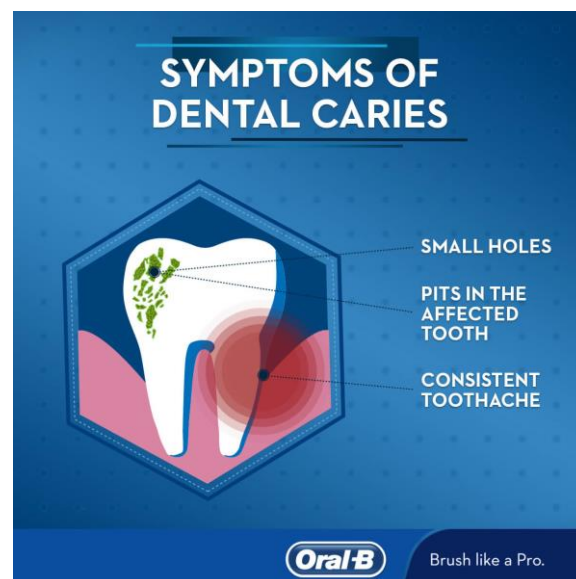
The etiology of caries is multifactorial and involves host factors such as salivary components, dietary factors such as the availability of fermentable carbohydrate and microbial factors.

The primary microbial agent in caries is the Gram-positive facultative anaerobe *Streptococcus mutans*. This organism exhibits the two cardinal properties required of a cariogenic agent: acid tolerance and acid production.

## What causes dental caries?

Typically, dental caries can be spotted on two specific areas of the teeth: occlusal caries, which form on the top most part of the tooth where food particles repeatedly come in direct contact with the teeth and interproximal caries, which are dental caries that form between the teeth. It is in these two locations where bacteria fester and pose a risk to your oral hygiene.

If the teeth and surrounding areas are not cared for properly, the bacteria will begin to digest the sugars left over from food in your mouth and convert it into acids as a waste product. These acids are strong enough to demineralize the enamel on your teeth and form tiny holes—the first stage of dental caries. As the enamel begins to break down, the tooth loses the ability to reinforce the calcium and phosphate structures of the teeth naturally through saliva properties and, in time, acid penetrates into the tooth and destroys it from the inside out.



## Dental Caries Treatments

Professionally, there are four main ways to deal with dental caries. These treatments carried out by a dental professional can help treat damage incurred from dental caries.

- **Fillings:** Fillings are the most common form of treatment for the disease. A dental professional drill into the affected area(s) of the teeth, removes the decayed material inside the prepared cavity, and packs this empty space with an appropriate dental filling material. There are different types of filling materials that can be used, depending on the area where caries has occurred. Composite resin, the most common filling material in the developed world, has a great pallet of color which dentists can use to repair caries damage to teeth that are visible when you smile. In the case of back teeth, some dentists prefer using other dental filling materials which are stronger.
- **Crowns:** Crowns are another option for dental professionals when treating dental caries, and are only used when a large proportion of the tooth is destroyed by disease. When tooth decay leads to the need for large fillings, the tooth becomes more prone to cracks and ultimately breaking. The dentist would attempt to salvage the remaining tooth, repair it, and finally fit the tooth with an alloy or porcelain crown covering.
- **Root Canal:** Another method of treatment that a dental professional may employ is called a root canal. As tooth decay progresses through the enamel and settles in the center of the tooth, it may even advance further and damage the nerves, which are in the root. A dental professional would remove the damaged or dead nerve with the surrounding blood vessel tissue (pulp) and fill the area. The procedure usually ends with the dentist placing a crown over the affected area.
- **Extraction:** In some cases, the tooth may be damaged beyond repair and must be extracted if there is risk of infection spreading to the jaw bone. The removal of some teeth may affect the alignment of those left in the mouth, so it is recommended that a partial denture, bridge, or implant be inserted in those edentulous areas

## How to Prevent Dental Caries

Despite the impact tooth decay can have on your teeth if left unattended, dental caries or cavities are largely preventable with a great oral hygiene regimen. This includes brushing at least twice a day with an electric toothbrush.

In fact, recent studies show that brushing regularly with an electric toothbrush can help prevent tooth loss by more effectively removing the plaque bacteria that can lead to tooth decay. Also, keep up with regular dental checkups in order to identify pre-existing conditions before they lead to more serious issues down the road. The earlier a dental professional can spot the signs of poor oral hygiene, such as a buildup of plaque, the better your chances at preventing dental caries and gum problems from ever occurring in the first place.

A few recommendations a dentist might make include:

- Brushing your teeth twice a day for at least two minutes using fluoride rinse, paste, or gel. We recommend Crest Pro-Health products which includes fluoride to help reduce the production of acid that can damage your teeth.
- Flossing regularly after brushing especially if one is frequently eating or drinking sugary foods or drinks. Certain foods high in sugar can provide a consistent supply of damaging acid to the tooth hard tissues. Flossing once or twice a day with Crest Pro-Health products can help you remove food particles from between the hard-to-reach areas of your teeth you might be missing.

### **Sites of Dental Caries**

- Pits and fissures on occlusal surfaces of molars and premolar
- Buccal pits of molars
- Palatal pits of maxillary incisors
- Enamel of the cervical margin of the tooth just coronal to the gingival margin
- Proximal enamel smooth surfaces apical to the contact point
- In teeth with gingival recession occurring because of periodontal disease
- The margins of restorations predominantly which are deficient or overhanging
- Tooth surfaces adjacent to dentures and bridges.

## 2.2. Etiology of Dental Caries

### Possible interventions

- Reduce intake of cariogenic sugars particularly sucrose
- Diet
- Bacteria
- Caries
- Time
- Possible interventions
- Susceptible
- Surface (Host)
- Avoid frequent sucrose intake (snacking)
- Stimulate salivary flow + sugar clearance
- Possible intervention
- Reduce *Streptococcus mutans* numbers by:
  - Reduction in sugar intake
  - Active or passive immunization
- Possible interventions
- Water + other types of
  - Fluoridation
  - Prevention during post-eruptive maturation
  - Fissure sealing
  - Properly contoured restorations

### Theories of Dental Caries

1. Acidogenic theory
2. Proteolytic theory
3. Proteolysis-chelation theory.

#### 1. Acidogenic Theory:

This states that Dental decay is a chemoparasitic process consisting of 2 stages:

Stage 1: Decalcification of enamel results in total destruction decalcification of dentin as a preliminary stage

Stage 2: Followed by dissolution of softened residue of enamel and dentine

## **2. Proteolytic theory:**

This states that the Organic portion of the tooth is attacked first with lytic enzymes. This leaves the inorganic portion of tooth without a matrix support causing it to be washed away creating cavities.

## **3. Proteolysis-Chelation theory:**

This states that the initial attack of dental caries is on the organic and inorganic portion of enamel simultaneously by formulation of substances that form soluble chelates with mineralized component of tooth.

## **Role of Carbohydrates**

Carbohydrates exert cariogenic effect which depends upon the following factors:

1. Frequency of intake
2. Chemical composition, for example, monosaccharides and disaccharides are more cariogenic than polysaccharides
3. Physical form like solid, sticky jelly like or liquid
4. Time of contact of carbohydrate with the tooth
5. Presence of other food components like presence of high fat or proteins makes carbohydrate less cariogenic.

## **Role of acids**

Acids play most important role in pathogenesis of dental caries. pH 5.5 is called critical pH. Below this pH demineralization of tooth substance begins found on un-cleaned tooth surfaces and appear as tenacious, thin film. It appears as tenacious, thin film.

## **Local Factors affecting the Incidence of Caries**

- Tooth (Host)
  - i) Variation in morphology
  - ii) Composition
  - iii) Position
  - iv)
- Microorganisms
- Substrate (Environmental factors)

- Saliva:
  - i) Composition
  - ii) Quantity
  - iii) Ph
    - v) Viscosity
    - vi) Antibacterial factors.

**Diet:**

- i) Physical factors
- ii) Local factors
  - Carbohydrate content: Presence of refined cariogenic carbohydrate particles on the tooth surface
  - Vitamin content
  - Fluoride content.
  - Fat content
  - Microorganisms: Most commonly seen microorganisms associated with caries are Streptococcus mutans and Lactobacillus.

**2.3 Classification**

1. Depending on nature of attack
2. Depending on progression of caries
3. Depending on surfaces involved
4. Based on direction of attack
5. Based on number of surfaces involved
6. GV Black Classification based on treatment and restoration design
7. Based on location of lesion
8. Based on tissue involved

**Nature of Attack**

- Primary Caries, incipient, initial first attack on tooth surface
- Secondary Caries: occurs on margins or walls of existing restorations. It is also known as recurrent caries.

## Direction of caries attack

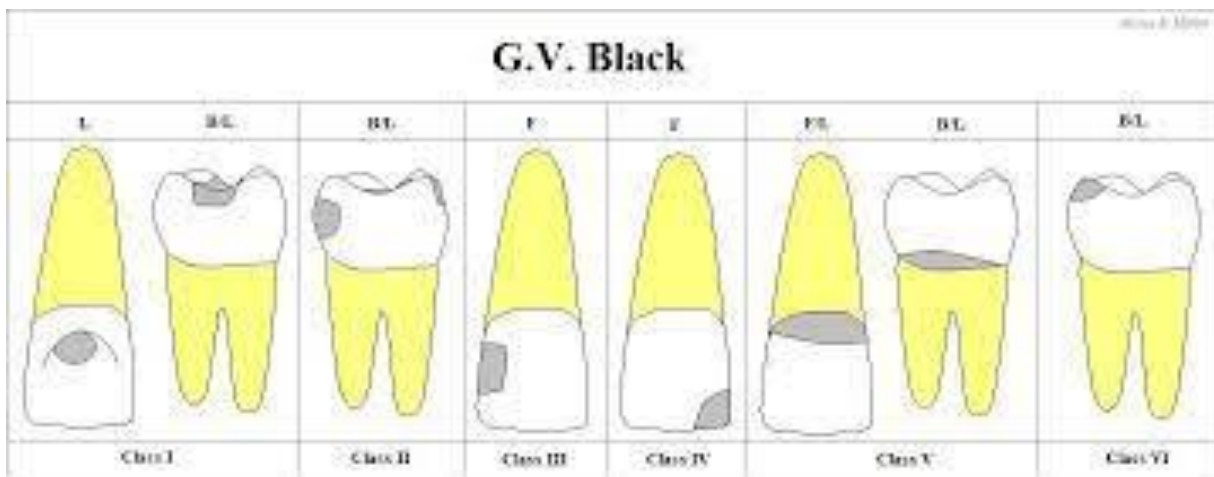
Proximal caries: proceeds from enamel to dentin. The lesion is triangle in shaped with base of triangle at enamel surface + apex towards dentin

**Pit and fissure caries:** occurs in pits + fissures. The base is at DEJ, apex is in the pit

## Number of Surfaces involved

- Simple: only one surface is involved by caries
- Compound: Two surfaces are involved
- Complex: more than 3 surfaces are involved

## GV Black Classification



- Class I: caries affecting pits and fissures on occlusal 3<sup>rd</sup> of molars and premolars; occlusal 2/3<sup>rd</sup> of molars and premolars; lingual part of anterior teeth
- Class II: caries affecting proximal surfaces of molars and premolars
- Class III: caries affecting the proximal surfaces of central incisors, lateral incisor and canines with involvement of the incisal angles.
- Class IV: Caries affecting proximal surfaces including incisal angles of anterior teeth
- Class V: caries affecting gingival 1/3<sup>rd</sup> of facial or lingual surfaces of anterior or posterior teeth
- Class VI: caries affecting cusp tips of molars, premolars and canines

### **2.3. Types of Cries:**

#### **Senile Caries**

Caries associated with ageing almost exclusively occurring on root surface

#### **Residual Caries**

Caries that have not been removed during restorative procedures

#### **Clinical Features:**

Usually occurs on cervical area. Typical cervical lesion is a crescent shaped cavity beginning as slightly roughened chalky area and gradually becomes excavated. They appears brown or black, feel slightly soft and catch a fine explorer point

#### **Recurrent Caries**

These occur immediately adjacent to restoration. They may be caused by inadequate extension of restoration (was not able to excavate or removed well original carious lesion)

#### **Nursing Bottle Caries**

##### **Etiology:**

Due to nursing bottle containing milk or milk formula, fruit juice or sweetened water. Sometimes it occurs due to sugar or honey-sweetened pacifier

#### **Rampant Caries**

Suddenly appearing, widespread and resulting in early involvement of pulp

##### **Etiology:**

May be due to nutritional deficiency, malnutrition and emotional disturbances

#### **Clinical Features:**

It occurs in children with poor dietary habits. They involve extensive inter-proximal + smooth surface caries

### **2.4. Prevention/Management of Dental Caries:**

- Restorative Treatment
- Tooth Brushing
- Mouth Rinsing
- Dental Floss



- Topical Fluoride Application (Pedo Patients)
- Pit and Fissure Sealants

### **Caries Prevention Methods:**

#### **Chemical Method:**

Flouride: Flouride alters the tooth surface and tooth structure to increase resistance to demineralization and prevent caries.

Flourides are used in following forms:

- Flouridation of water supplies
- Topical application of:
  - i) Sodium fluoride (NaF)
  - ii) Stannous fluoride (SnF<sub>2</sub>)
  - iii) Acidulated flourido-phosphate
  - iv) Prophylactic paste
  - v) Flouride dentifrices
  - vi) Flouride mouthwashes or rinses
    - Chlorhexidine
    - Zinc Chloride
    - Caries Vaccine
    - Vitamin K

#### **Dietary Method:**

Caries can be prevented by restriction of refined carbohydrate intake. Sucrose is most cariogenic. Hence its use in food should be restricted.

#### **Mechanical Methods:**

- Tooth Bruhing
- Dental Floss
- Mouth rinsing
- Pit and fissure sealants

## Chapter: 3

### PERIODONTOLOGY

#### **Objective:**

To develop concept of Healthy periodontium, diagnosis of common periodontal diseases and their treatment.

#### **3.1. Overview**

A healthy or a stable periodontium is an important prerequisite both for the maintenance of a functional dentition and to ensure a long-term successful outcome of restorative dental treatment. In view of the high prevalence of gingivitis and chronic periodontitis in the population, all dental patients should undergo periodontal screening, although more thorough clinical and radiographic examinations are essential before a definitive periodontal diagnosis is confirmed and a treatment plan is formulated. These examinations, together with medical, dental and social histories may also reveal predisposing and risk factors that increase an individual's susceptibility and the subsequent rate of progression of periodontal disease.

The intensive oral hygiene phase of treatment and the patient's compliance with a personalised plaque-control regimen are of major importance in stabilizing the disease and improving the long-term prognosis for an affected dentition. Scaling and root surface instrumentation (RSI) are frequently indicated to disrupt the subgingival biofilm and remove calculus. Additional adjunctive treatments that may be indicated are periodontal surgery, guided tissue regeneration (GTR), systemic or locally delivered antimicrobials and the management of localised problems such as furcation defects, mucogingival problems, periodontal–endodontic lesions and loss of attachment that has been exacerbated by a traumatic occlusion.

#### **3.2. Healthy periodontium**

The diagnostic skills required to identify periodontal diseases, particularly in the early stages, are based upon a sound knowledge of the clinical appearance of healthy tissues.

#### **Clinical features**

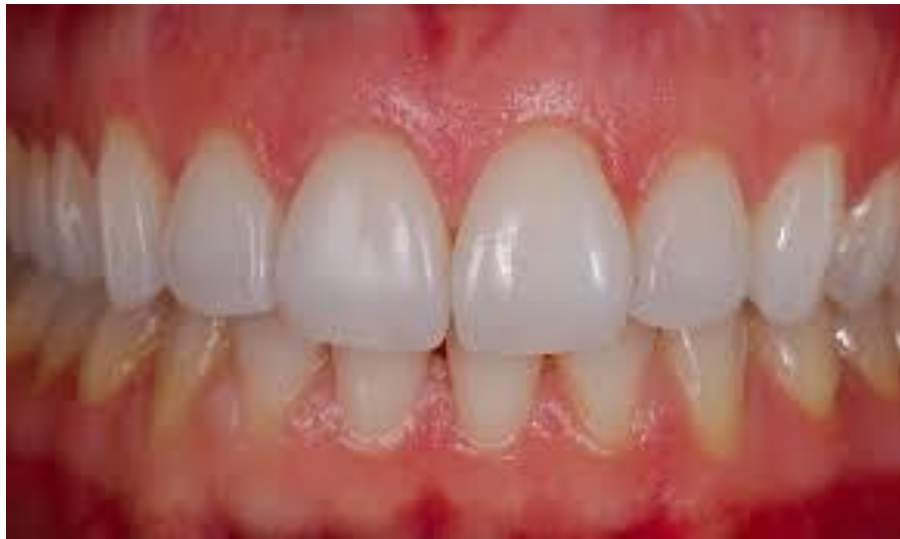The gingiva is pink, firm in texture and extends from the free gingival margin to the mucogingival line. The interdental papillae are pyramidal in shape and occupy the interdental spaces beneath the contact points of the teeth. Gingiva is keratinized and

stippling is frequently present. The gingiva comprises the free and the attached portions.

The free gingiva is the most coronal band of unattached tissue demarcated by the free gingival groove, which can sometimes be detected clinically. The depth of the gingival sulcus ranges from 0.5 to 3.0 mm.

The attached gingiva is firmly bound to underlying cementum and alveolar bone and extends apically from the free gingival groove to the mucogingival junction. The width of attached gingiva varies considerably throughout the mouth. It is usually narrower on the lingual aspect of the mandibular incisors and labially, adjacent to the canines and first premolars. In the absence of inflammation, the width of the attached gingiva increases with age.

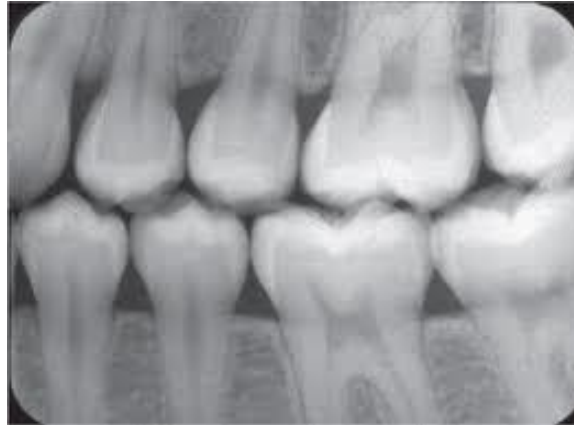The mucogingival line is often indistinct. It defines the junction between the keratinised, attached gingiva and the oral mucosa. Oral mucosa is non-keratinised and, therefore, appears redder than the adjacent gingiva. The tissues can be distinguished by staining with Schiller iodine solution; keratinised gingiva stains orange and non-keratinised mucosa stains purple–blue. This can be used to determine clinically the width of keratinised tissue that remains (e.g. in areas of gingival recession).



**Figure:** Healthy Periodontium

## **Radiographic features**

The crest of the interdental alveolar bone is well defined and lies approximately 0.5–1.5 mm apical to the cemento-enamel junction. The periodontal membrane space, often identifiable on intraoral radiographs taken using a paralleling technique, is approximately 0.1–0.2 mm wide. This accounts for the slight tooth mobility that is sometimes observed when lateral pressure is applied to a tooth with a healthy periodontium.

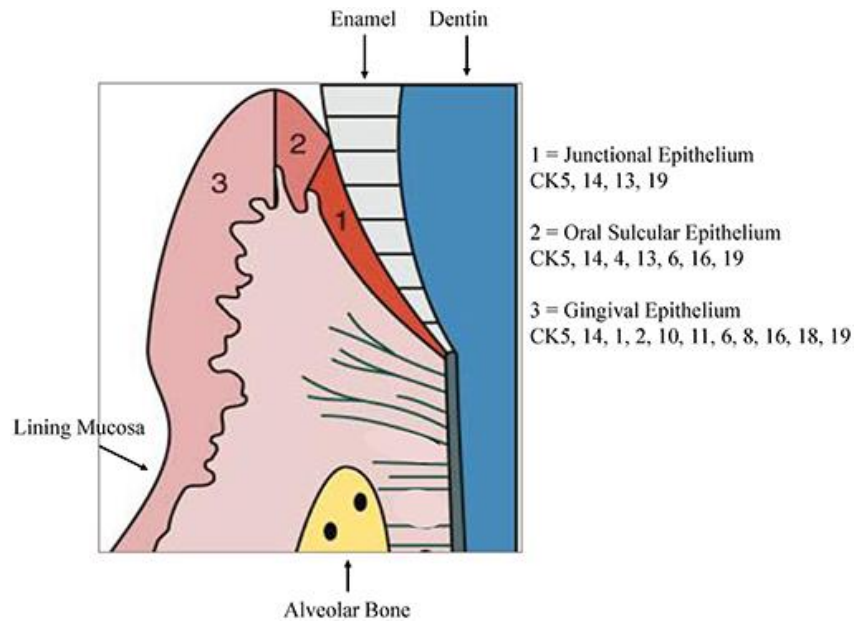


**Figure:** Radiographic appearance of healthy periodontium

### **3.3. Histology**

#### **Epithelial components include:**

- Junctional epithelium cells: non-keratinised and attached to the tooth surface by a basal lamina and hemidesmosomes
- Sulcular epithelium: non-keratinised and lines the gingival crevice
- Oral epithelium: keratinised and extends from the free gingival margin to the mucogingival line.



**Figure:** Epithelial components of periodontium

Gingival connective tissue core contains ground substance, blood vessels and lymphatics, nerves, fibroblasts and bundles of gingival collagen fibers (dentogingival, alveologingival, circular and trans-septal). The combined epithelial and gingival fiber attachment to the tooth surface is the biologic width, which is typically 2 mm, not including the sulcus depth (see Fig. 1.1).

Periodontal connective tissues comprise alveolar bone, periodontal ligament, principal and oxytalan fibers, cells, ground substance, nerves, blood vessels and lymphatics, and cementum.

### Periodontal Tissues in Children

The gingiva in children may appear red and inflamed. Compared with mature tissue. There is a thinner epithelium that is less keratinised, greater vascularity of connective tissues and less variation in the width of the attached gingiva.

During tooth eruption, the gingival sulcus depths may reach 5 mm and gingival margins will be at different levels on adjacent teeth. Following tooth eruption, a persistent hyperemia can lead to swollen and rounded interproximal papillae, thus giving an appearance of gingivitis.

## **Radiographic features**

In the primary dentition, the radiographic distance between the cemento-enamel junction (CEJ) and the alveolar crest is 0–2 mm. Greater variation (0–4 mm) is observed at sites adjacent to erupting permanent teeth and exfoliating primary teeth. The periodontal membrane space is wider in children because of the thinner cementum, immature alveolar bone and a more vascular periodontal ligament.

## **Gingival Crevicular Fluid**

Gingival crevicular fluid (GCF) is a serum exudate that is derived from the microvasculature of the gingiva and periodontal ligament. The 'pre-inflammatory' flow of GCF may be mediated by bacterial products from subgingival plaque that diffuse intercellularly and accumulate adjacent to the basement membrane of the junctional epithelium. This creates an osmotic gradient; consequently, GCF flow can be regarded as a transudate rather than an inflammatory exudate.

GCF is, in some ways, similar to serum but also contains components from microbial sources, interstitial fluid and locally produced inflammatory and immune products of host origin. The proportions of these components are dependent upon:

- Presence and composition of subgingival plaque
- Rate of turnover of gingival connective tissue
- Permeability of epithelia
- Degree of inflammation. Several techniques have been developed for collecting GCF from the gingival sulcus:
  - Absorbent paper strips
  - Microcapillary tubes
  - Gingival washing.

The fluid can then be analysed for specific mediators of the immune-inflammatory response (e.g. cytokines) and breakdown products of connective tissues, both of which have been associated with ongoing periodontal destruction.

### **3.4. History and Clinical examination**

From the periodontal viewpoint, the aims of history taking and the clinical examination are to establish the extent of periodontal destruction and to evaluate the effects of disease on the remaining dentition. It is also important to evaluate the individual patient's susceptibility to periodontal disease and, as far as possible, identify the sites

that appear to be associated with active or ongoing destruction and need to be considered a priority for treatment.

### **Presenting Complaint**

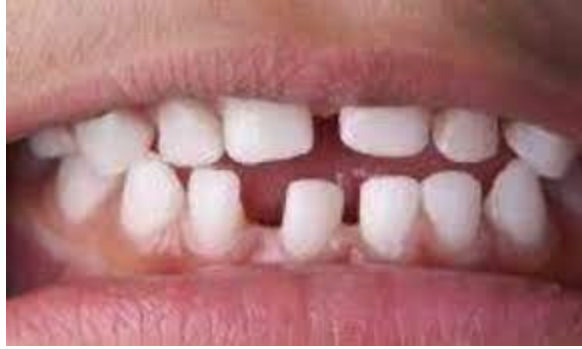One of the principal features of periodontal diseases is that their onset and progression occur often in the absence of pain. This means that the onus for detection rests firmly with the clinician, and the importance of regular examinations must be impressed upon the patient, with emphasis placed on prevention rather than cure. The well-informed patient who is a regular dental attender should be able to detect some of the signs or symptoms that are associated with the early stages of plaque accumulation. Unfortunately, many patients are irregular dental attenders and only present with complaints that are the consequence of oral neglect. When gingivitis and periodontal inflammation do cause symptoms, the chief complaints are usually 'bleeding gums', 'bad taste or breath', 'localised pain' and teeth that have 'changed position' or 'become loose'. Details of when such problems started, the frequency of pain or discomfort and any associated symptoms should be recorded. The expectations of the patient with regard to the outcome of treatment should also be discussed at this stage.

### **Gingival bleeding**

Bleeding gums is perhaps the most common complaint of patients with periodontal disease. The bleeding is usually noticed during, or following, tooth brushing or eating. When bleeding occurs spontaneously, a patient may complain of tasting blood on awakening in the morning. The severity of the hemorrhage does not necessarily relate to the severity of disease, as a marginal gingivitis can be associated with quite profuse bleeding. Gingival bleeding is exacerbated by the use of certain drugs (anticoagulants, anti-thrombotics and fibrinolytic agents). Symptoms of relatively recent and sudden onset should be investigated thoroughly when taking the medical history.

### **Drifting of teeth**

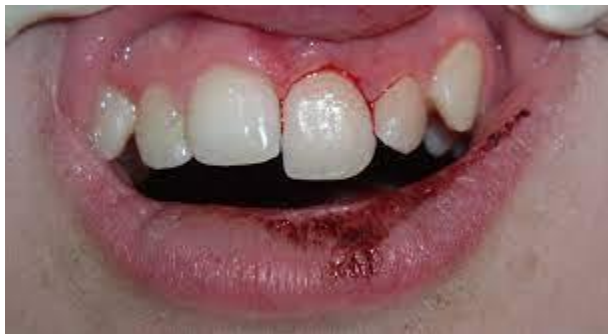Drifting of anterior teeth and the appearance of spaces between teeth are often the first signs of an underlying periodontal problem. When teeth begin to drift, it is because their periodontal support has been compromised to such an extent that the teeth are no longer in equilibrium with forces from occlusion and the adjacent soft tissues. In some instances, this position of equilibrium is so finely balanced that the destruction of only crestal bone and the coronal periodontal fiber groups will precipitate changes in tooth position. Furthermore, the pressures exerted on the teeth by gingiva that are swollen through edematous or fibrous change can also induce tooth movement. Drifting of anterior teeth may also be a consequence of an occlusal interference in the posterior segments, which leads to a forward slide of the mandible during its arc of movement from the retruded contact position to the intercuspal position.



**Figure:** Clinical appearance of drifted teeth

### **Loose teeth**

When periodontal disease remains untreated, attachment loss is progressive and teeth become increasingly mobile. The degree of mobility that some patients accept before attending for treatment is remarkable and many patients still believe that increasing tooth mobility and, ultimately, tooth loss is a natural consequence of the ageing process. An increase in mobility also occurs when a tooth is subject to increased or abnormal occlusal forces, particularly those of a 'jiggling' nature. Mobility may be the first signs of an advanced stage of periodontitis or perhaps a rapidly progressive, or aggressive, type of disease.



**Figure:** Clinical appearance of loose teeth

### **Bad taste and halitosis**

Altered sensation of taste can accompany the halitosis (foul smelling breath) that is associated with:

- Necrotising ulcerative gingivitis (NUG)
- Purulent exudate from a periodontal abscess



- Poor oral hygiene/accumulated food debris from packing beneath open contact points, in furcations, beneath overhanging or leaking restorations and associated with dentures
- Excessive bacterial growth on the dorsal surface of the tongue.

## **Pain**

Acute and often quite severe pain is a feature of NUG and herpetic gingivo-stomatitis. Pain, particularly on eating, is also a symptom of an acute periodontal abscess and/or a periodontal–endodontic lesion. Gingival recession with exposure of root surfaces can also precipitate pain if dentine is exposed as a result of toothbrush abrasion. This pain is characterised as sharp and transient, with a sudden onset that is precipitated by extremes of temperature. Pain, however, is not typically a feature of chronic periodontitis.

### **3.5. Dental History**

The dental history provides an indication of the patients' overall attitude to dental care. Lengthy intervals between appointments and attendance for only symptomatic treatment suggest a low priority on dental health and a patient who is unlikely to appreciate and comply with comprehensive periodontal care.

The reasons for previous loss of teeth should be established and a record made of previous and recent dental treatment. Information (including radiographs) relating to previous dental treatment should, whenever possible, be sought by written request from a previous dentist, and the written response incorporated in the patient's notes. Another criterion sometimes used to assess dental behaviour is the frequency with which a patient brushes (or claims to brush) his or her teeth. It is more important to assess the efficiency of the method of toothbrushing rather than to place too much emphasis on frequency. An individual who brushes once a day for 4–5 minutes is often able to maintain a superior standard of oral hygiene than a patient who brushes several times a day, but ineffectively and for only short periods of time.

In young patients in particular, a note should be made of previous orthodontic treatment. Extended periods of fixed appliance therapy can cause loss of crestal alveolar bone partly from tooth movements and partly from the periodontal inflammation that is a consequence of limited access to cleaning interproximal and subgingival regions. More importantly from the diagnostic viewpoint, teeth that have been tipped rather than moved bodily through bone often have an angular alveolar crest on the mesial and distal surfaces. Such topography gives the appearance of the lesions often seen in localised aggressive periodontitis.

### **3.6. Social History**

Details of the patients' occupation, diet and consumption of alcohol and tobacco should be noted. When an occupation involves considerable social contact, there may be a greater awareness of small changes of tooth position and appearance.

Stress induced by examinations, divorce or change of employment, peer pressures should also be noted as they may promote bruxism and aggravates existing tooth mobility from periodontal disease. Stress has been shown to be associated with delayed wound healing of connective tissue and bone, NUG and, maybe, chronic periodontitis. As most patients have some element of stress in their lives, the potential influence of this on periodontal disease should be appreciated. A lack of ability to cope with stress, and particularly financial strain, has been implicated as a specific risk factor in periodontal disease.

Smoking is a known risk factor for periodontal disease and is considered in Section 1.6. The frequency and duration of smoking should be established and the detrimental effects of smoking on periodontal health must be conveyed to the patient before any treatment is started.

It should now be apparent that much of the information that can be derived from a thorough personal and dental history has a bearing on establishing the susceptibility of an individual to periodontal disease. When potential risk factors are established, it is often not possible to determine their individual effects on the disease process because many of the factors are inter-related. For example, an individual who has job insecurity and is under financial strain may be also a smoker and a poor dental attender.

### **3.7. Medical History**

A thorough medical history must be recorded and updated at each visit. The patients' perception of their present health status is also a valuable indicator of their psychological make-up and potential compliance with treatment.

A patient with a history of rheumatic fever, congenital cardiac defects or prosthetic heart valves does not require antibiotic prophylaxis before periodontal probing and treatment. Similarly, patients who have received prosthetic joint implants do not require antibiotic prophylaxis. Ultrasonic scalers can be used in patients with cardiac pacemakers in accordance with the manufacturers' guidance, which normally recommends that the ultrasonic handpiece and cables should be kept at least 15 cm away from the pacemaker device.

Diabetic patients are at particular risk of periodontal breakdown, especially when poorly controlled. A positive family history should be noted and vigilant periodontal monitoring

undertaken. The HIV-positive patient is also at risk from very extensive and aggressive periodontal breakdown.

Patients with particular food trends or unusual diets should be questioned as part of an overall dietary analysis to evaluate their vitamin and protein intake. Nutritional deficiencies may modify the severity and extent of periodontal disease by altering the host resistance and potential for repair.

Gastric hyperacidity and reflux from hiatus hernia and gastric ulceration predispose to erosion and root caries if there is existing gingival recession. Pregnant patients should be monitored carefully during the second and third trimesters as endocrine changes may lead to marked gingival inflammation and the development of epulides. Radiographic assessment of periodontal disease should be avoided during pregnancy.

Current medications must be noted, especially dosage and types of medication. When a patient is receiving anticoagulant therapy, the general medical practitioner or patients' physician must be consulted with a view to modifying the anticoagulant dosage to coincide with invasive periodontal treatment, thus reducing the risk of postoperative hemorrhage. Some drugs such as phenytoin, ciclosporin and nifedipine can cause gingival overgrowth, which may compromise good oral hygiene, leading to aesthetic problems. For patients taking bisphosphonates, extractions and osseous surgery should be avoided due to the risk of osteonecrosis. Antimicrobials often used in the treatment of periodontal diseases are contraindicated for certain patients for whom the unwanted effects of the drugs may be enhanced, or because of a potential interaction with drugs that the patient is already taking.

### **3.8. Clinical Examination**

#### **Extraoral examination**

A careful extraoral examination may reveal important signs that are associated with periodontal problems. A severe periodontal abscess can lead to facial swelling and a regional lymphadenopathy. Prominent maxillary incisors make a lip seal difficult to achieve and this may aggravate an existing gingivitis. The drying effect on exposed gingiva produced by mouth breathing leads to enlarged and erythematous gingiva, particularly in the maxillary anterior region. Mouth breathing does not inevitably lead to increased plaque accumulation and gingivitis but should be regarded as a predisposing factor in a susceptible patient.

## **Intraoral examination**

A record should be made of local factors that predispose to the accumulation of plaque (e.g. restorations with overhanging margins, poorly contoured and deficient restorations and partial dentures).

A quick and simple method of assessing the level of oral hygiene is to score, after disclosing, the number of plaque-covered smooth tooth surfaces as a percentage of all smooth surfaces. On each surface, plaque is recorded as being either present or absent (a dichotomous scoring method). Patients are informed of their scores and realistic targets can be set for the patient to achieve at future visits. This method gives a useful overall assessment of plaque control as well as identifying tooth surfaces that are difficult to clean. These occur typically at interproximal sites and on the lingual smooth surfaces of mandibular molars. A number of indices have been used for scoring plaque, oral debris and calculus on a quantitative basis. Periodontal diseases and gingivitis occur in all patients regardless of age. Chronic periodontitis is prevalent in adults and gingivitis is extremely common in children. Furthermore, children and young adults are also at risk from the more aggressive, early-onset diseases. It is, therefore, imperative that all dental patients undergo a screening examination to provide a rapid, basic assessment of periodontal status.

The Basic Periodontal Examination (BPE) has evolved from the Community Periodontal Index of Treatment Needs (CPITN) and is a quick method for assessing a patient's periodontal status. The examination involves the use of a specially designed periodontal probe with a 0.5-mm diameter ball end and a coloured band extending 3.5–5.5 mm from the tip. The dentition is divided into sextants; each tooth is probed circumferentially and only the highest score in each sextant is recorded. The score codes are used as a guide to determine the need for periodontal treatment. A BPE score of 3 means that full probing depths (six sites per tooth) around all the teeth in that sextant should be recorded. A score of 4 in any sextant means that probing depths should be recorded throughout the entire dentition.

### **3.9. Basic Periodontal Examination (BPE)**

<b>Code</b>	<b>Probing</b>	<b>Treatment needs</b>
<b>0</b>	Coloured area of the probe is completely visible; no calculus detected; no gingival bleeding on probing	No need for periodontal treatment
<b>1</b>	Coloured area is completely visible; no calculus detected; bleeding on probing	Oral hygiene instructions (OHI)
<b>2</b>	Coloured area is completely visible; supra- or subgingival calculus detected, or overhanging restorations	OHI; elimination of plaque-retentive areas; scaling and RSI
<b>3</b>	Coloured area is partly visible, indicating probing depth of greater than 3.5 mm but less than 5.5 mm	OHI; elimination of plaque-retentive areas; RSI
<b>4</b>	Coloured area completely disappears, indicating probing depth of greater than 5.5 mm	Assess the need for more complex treatment in addition to OHI and RSI; referral to a specialist may be necessary

The symbol (\*) should be added to score where furcation involvement is evident

#### **Gingiva**

Visual examination of the gingiva may reveal colour changes of the tissues, gingival swelling (generalised or localised), ulceration, suppuration and gingival recession. Where there is gingival enlargement, the tissues should be probed gently to assess consistency and texture. Edematous tissues are soft and may have a tendency to bleed spontaneously or following pressure and gentle manipulation. Conversely, fibrous tissue is usually quite firm and resistant to pressure.

The width of attached gingiva should be assessed and measured as the distance from the free gingival margin to the mucogingival line minus the depth of the gingival crevice (in health) or periodontal pocket (when disease is present). Sites with minimal or no apparent attached gingiva should be noted together with the inflammatory condition of the associated marginal tissues. At such sites, the attached gingiva can be dyed with Schiller iodine solution so that the border between the keratinised (orange) and non-keratinised (dark blue) epithelium (mucogingival junction) is seen and the actual width of keratinised tissue becomes more readily apparent. Sites of gingival recession are recorded by measuring from the CEJ to the free gingival margin of the affected site. Sensitivity of associated exposed root surfaces should also be recorded.

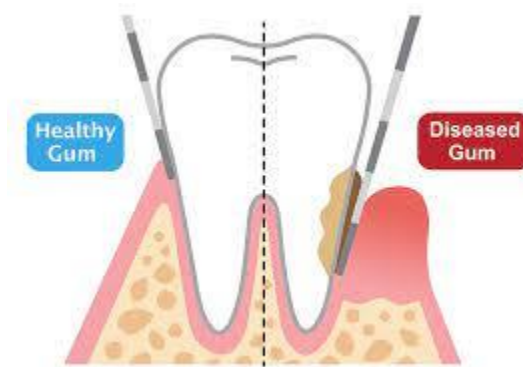
The presence of a prominent labial frenum may effectively reduce the width of attached gingiva, although the precise role of a frenal attachment as a predisposing factor to gingival recession is disputed. A prominent frenum can, however, reduce sulcus depth and restrict access for tooth brushing and it can thus lead to the development of local periodontal problems.

### **Periodontal probing**

Periodontal probing should be undertaken systematically on each tooth to determine the probing depth, the presence of bleeding after probing and the extent of attachment loss. The probe should be moved gently around the sulcus to avoid trauma. A force of approximately 0.25 N is recommended, but this is difficult to achieve consistently without the use of a pressure-sensitive probe. An attempt should be made to probe along the contour of the root surface. It is necessary to angle the probe slightly at interproximal areas in order to reach the site directly beneath the contact area. This site should be probed from the buccal and the lingual aspects since deep pockets frequently develop here.

A number of factors may lead to errors in measuring probing depths:

- Thickness of the probe.
- Contour of the tooth surface.
- Angulation of probing.
- Pressure applied.
- Presence of calculus deposits.



**Figure:** Periodontal probing

The extent of inflammation is also important. A probe will more easily penetrate the pocket epithelium and the adjacent connective tissues when the tissues are inflamed. A probing depth measurement is influenced by the position of the gingival margin and the integrity of the tissues at the base of the pocket, and these factors are dependent upon the extent of inflammation in the tissues. Attempts have been made to reduce probing errors by using constant pressure probes and, more recently, electronic probes. In addition, computer-assisted probes have been developed for automatic recording of probe measurements or to allow voice-activated data entry. These probes have a high degree of resolution, measuring with a precision of 0.1–0.2 mm, but their accuracy and repeatability still depends upon angulation and positioning of the probe.

A more precise assessment of the degree of periodontal destruction is made by measuring from the CEJ to the base of the pocket. This gives an approximation of the loss of connective tissue attachment to the root surface. The loss of attachment is easier to measure when there has been gingival recession and the CEJ is visible. When patients are being monitored longitudinally before and after treatment, sequential attachment level measurements can be made relative to a fixed point (e.g. an incisal edge or cusp tip). The differences between successive measurements then give an estimate of the change in attachment level, which is often used to assess the success or failure of a particular treatment.

About 20–30 seconds after probing, each site is re-evaluated to determine the presence or absence of bleeding from the base of the pocket. Bleeding is simply a consequence of the trauma caused by probing the epithelial pocket lining and connective tissue. Bleeding on probing has been implicated as an indicator of active disease. Longitudinal clinical trials, however, suggest that bleeding has a low sensitivity for disease progression. Conversely, absence of bleeding is a good indicator of periodontal health or inactivity. Any site with a probing depth of less than 4 mm that does not exhibit bleeding on probing is not likely to require treatment beyond supragingival scaling and polishing.

### **Furcation involvement**

A curved explorer is used to determine the topography of the furcation lesion in multirooted teeth, allowing accurate classification into three groups.

Class I has initial involvement. The tissue destruction does not exceed more than 3 mm (or not more than one-third of the tooth width) into the furcation.

Class II includes cul-de-sac involvement. The tissue destruction extends deeper than 3 mm (or more than one-third of the tooth width) into the furcation but does not completely pass through the furcation.

Class III has through-and-through involvement. The lesion extends across the entire width of the furcation; consequently, an instrument can be passed between the roots to emerge on the other side of the tooth.

### **Tooth mobility**

Mobility is assessed by applying a labiolingual, horizontal force to each tooth in turn using the handles of dental mirrors. Movement is scored according to a simple index, such as:

- 0- Normal, physiological mobility (<0.3 mm)
- 1- Horizontal mobility up to 1.0 mm
- 2- Moderate horizontal mobility of 1.0–2.0 mm
- 3- Severe mobility >2.0 mm in horizontal plane or vertical movements

### **Radiographic evaluation**

Radiographic selection criteria for periodontal disease should take into account the diagnosis made from the clinical examination and the overall state of the patient's dentition. The panoramic radiograph, particularly if obtained using modern machines, is an alternative to full mouth periapical radiography on the basis of diagnostic yield of clinically unsuspected patterns of bone loss. In the posterior segments, vertical bitewings are often a useful supplement if a panoramic view suggests bone loss localised to this region.

Radiographic features that can be identified includes:

- Pattern of bone loss: horizontal/vertical, localised/generalised
- Furcation involvement
- Variation in root anatomy
- Subgingival calculus
- Widening of the periodontal membrane space
- Periapical infection (periodontal–endodontic lesions)
- Overhanging restorations.

A decreased alveolar bone height on a radiograph is only a historical record of previous periodontal involvement and gives little, if any, information on recent or current activity.

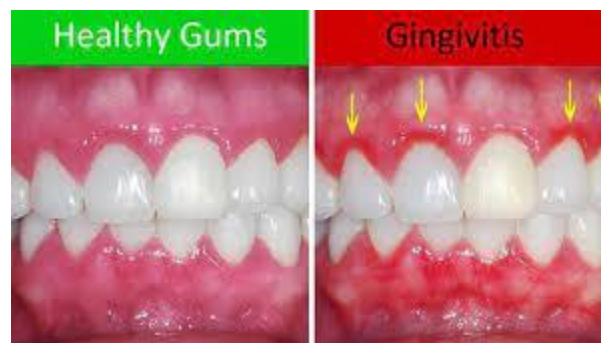

## Gingivitis

### Chronic Gingivitis

Chronic gingivitis is a plaque-induced, inflammatory lesion of the gingiva. Accumulation of dental plaque in the gingival sulcus initiates the development of an inflammatory lesion (subclinical) that, after 10–20 days, is detected clinically as an established chronic gingivitis.

Gingivitis occurs in 32% of 5-year-olds, 63% of 9-year-olds and 52% of 15-year-olds (O'Brian 2003). There has been no reduction in the prevalence of gingival inflammation in children over the 20-year period between 1983 and 2003 (Fig. 1.3). Indeed, in the 5-, 8- and 12-year-old age groups, there were more children with gingival inflammation in successive decades (1983–2003) although, in 15-year-olds, the proportion of children with gingival inflammation appears to be stable (48–52%).



**Figure:** Clinical appearance of Healthy gums and inflamed gums (gingivitis)

### Clinical features

The gingiva becomes red, shiny, swollen and soft or spongy in texture. Sulcus depths increase (false pockets) as a result of the tissue swelling from inflammatory edema. Bleeding occurs after gentle probing. The interdental papillae and marginal gingiva are initially involved before inflammation spreads to the attached gingiva.

### Treatment

- Instructions for tooth brushing.
- Use of interdental cleaning aids.
- Supragingival scaling.

- Elimination of plaque-retentive factors.
- Subgingival scaling and polishing.

### **Pregnancy Gingivitis**

An increase in circulating levels of estrogen, progesterone and their metabolites may aggravate a pre-existing gingivitis. The hormones and their metabolites effect an increase in gingival vasculature and the permeability of the capillary network. A similar increase in the severity of gingivitis may also be seen at, or around, puberty.

### **Clinical features**

Pregnancy gingivitis is a generalised, marginal, edematous inflammation. The extent of gingival enlargement is variable but an increase in gingival bleeding is a common complaint. The severity of the gingivitis tends to increase from the second to the eighth month of pregnancy. There is often some resolution during the final trimester and after parturition. A local gingival overgrowth (i.e. pregnancy epulis) may result from chronic irritation or mild trauma to the soft tissues.

### **Treatment**

A preventive regimen is preferred whenever possible. Otherwise a conventional treatment approach including oral hygiene instruction (OHI) and scaling should be undertaken.

## Chapter: 4

### DENTAL MATERIALS

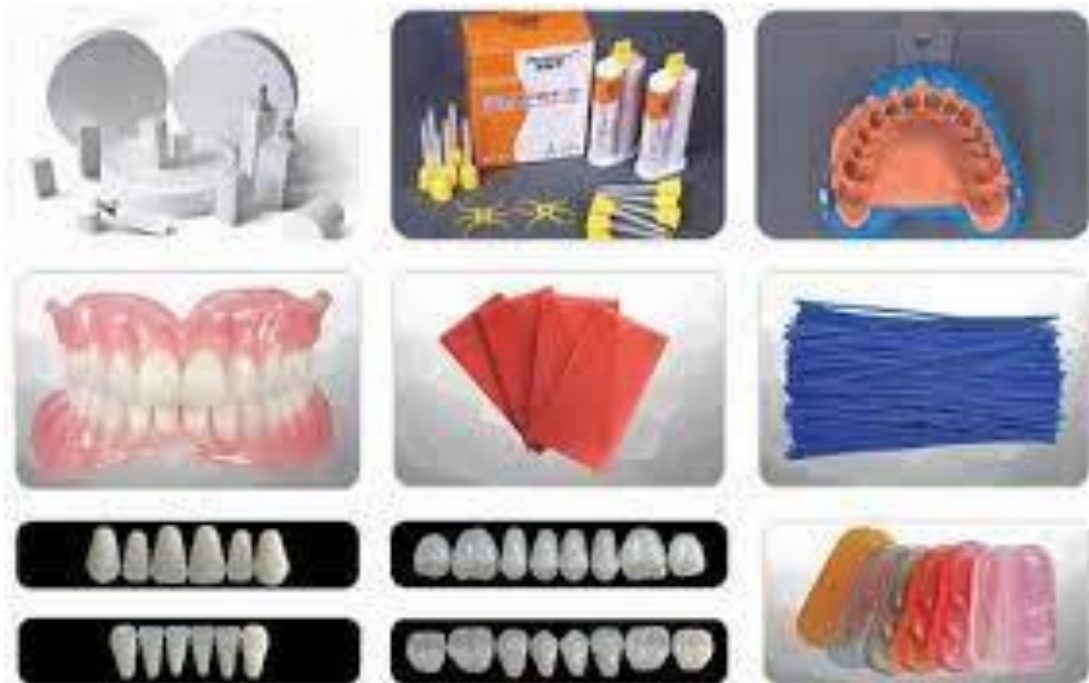#### Objective:

To develop know how of properties, types and application of commonly used Dental materials

#### 4.1. What is Dental Materials?

It is the study and Science of development, properties, manipulation, care, evolution and evaluation of materials used in the treatment and prevention of dental disease.

It specifically includes the principles of engineering, chemistry, physics and biology.



Dental materials are specially fabricated materials, designed for use in dentistry. There are different types of dental material, and their characteristics vary according to their intended purpose. Examples include temporary dressings, dental restorations, endodontic materials, impression materials, prosthetic materials, dental implants, and many others.

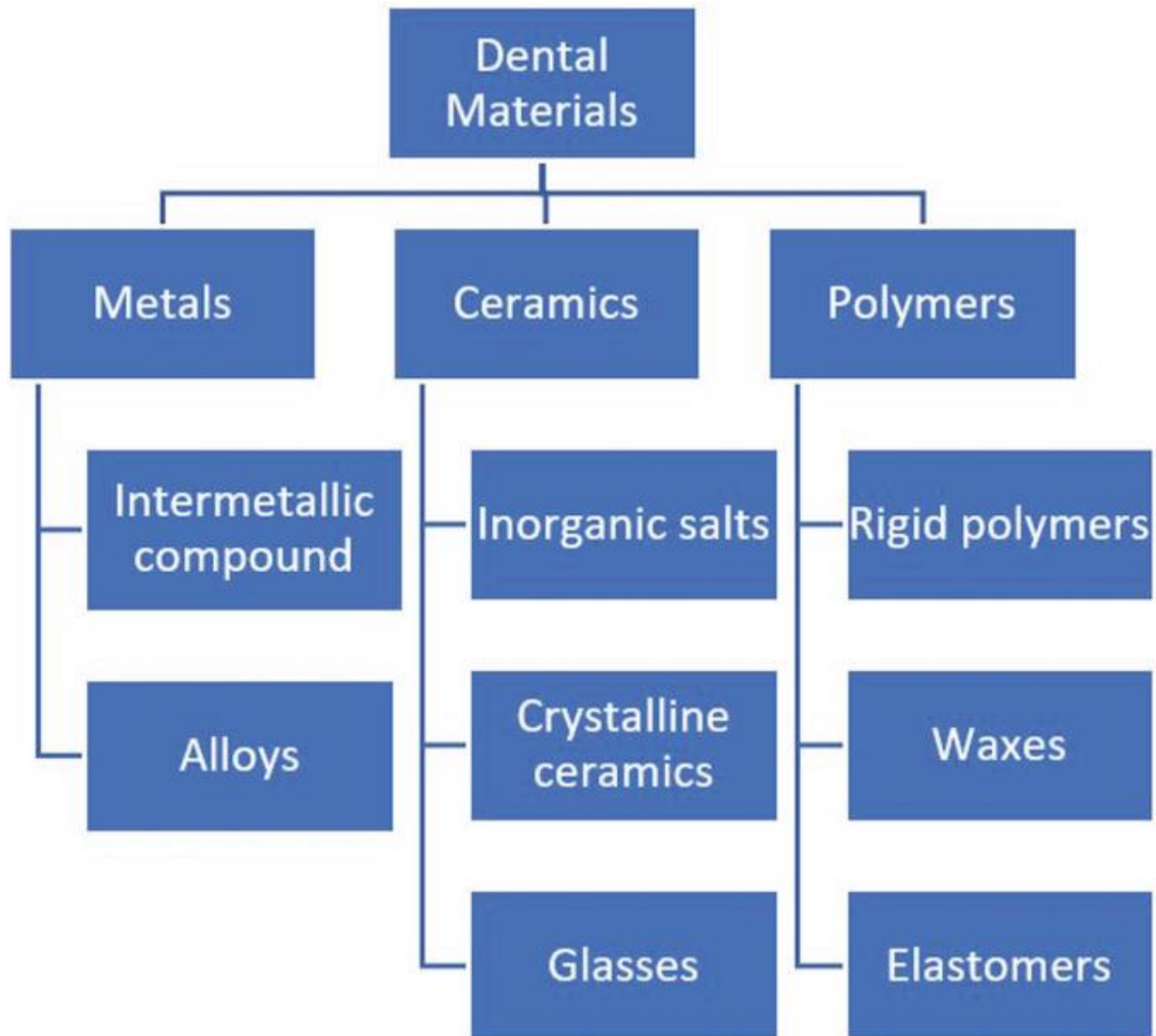
## **Importance of Studying Properties of Materials**

- Materials used to replace teeth or parts of teeth must withstand oral environment and forces of mastication
- Materials must be cleaned and polished by a variety of materials
- Clinical experience and research relate clinical success to certain properties of materials
- Critical physical properties are established which protects the public

## **4.2. Classification of Dental Materials**

### **Classifications of Dental Materials by Use**

1. **Restorative Materials**
2. **Restorations & Crowns**
3. **Bridges**
4. **Complete & Partial Dentures**
5. **Impression Casts & Models**
6. **Cements**
7. **Temporary Materials**
8. **Preventive Materials**
9. **Polishing Materials**
10. **Implants**
11. **Specialty Materials**

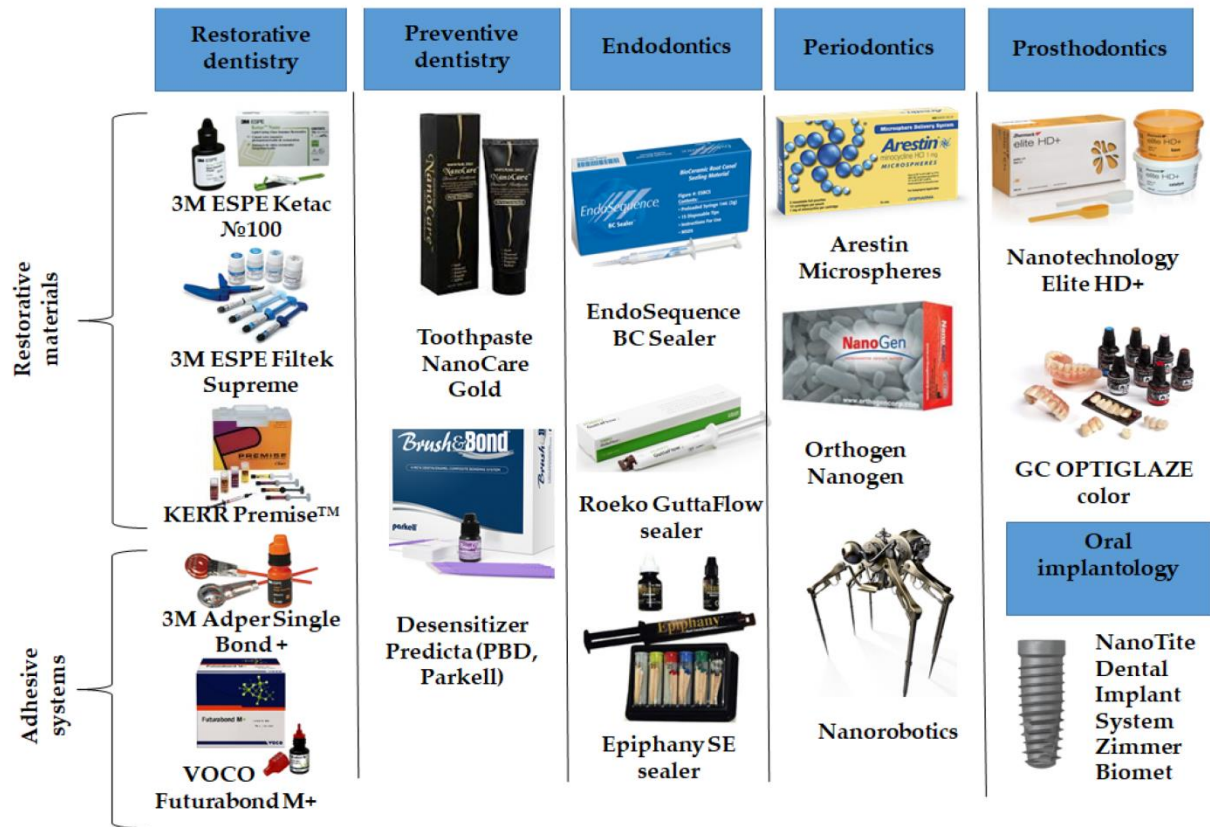


### Classification by Function

The first category is **preventive dental materials**. The definition of this type is the Reagent used to prevent the progression of tooth decay. For example, Cement, coating, or restorative material that either seals pits and fissures or releases a therapeutic agent such as fluoride and mineralizing ions to prevent or arrest the demineralization of tooth structure

The second category is **restorative dental materials**. It can be further divided into two types which are Direct Restorative Materials and Indirect Restorative Materials.

The last category is **auxiliary dental materials**. This type of material is used in the construction of a dental prosthesis but does not become a part of the structure.



### 4.3. Properties of Dental Materials

- I. Physical Properties
- II. Thermal Properties
- III. Electrical Properties
- IV. Optical Properties
- IV. Mechanical Properties

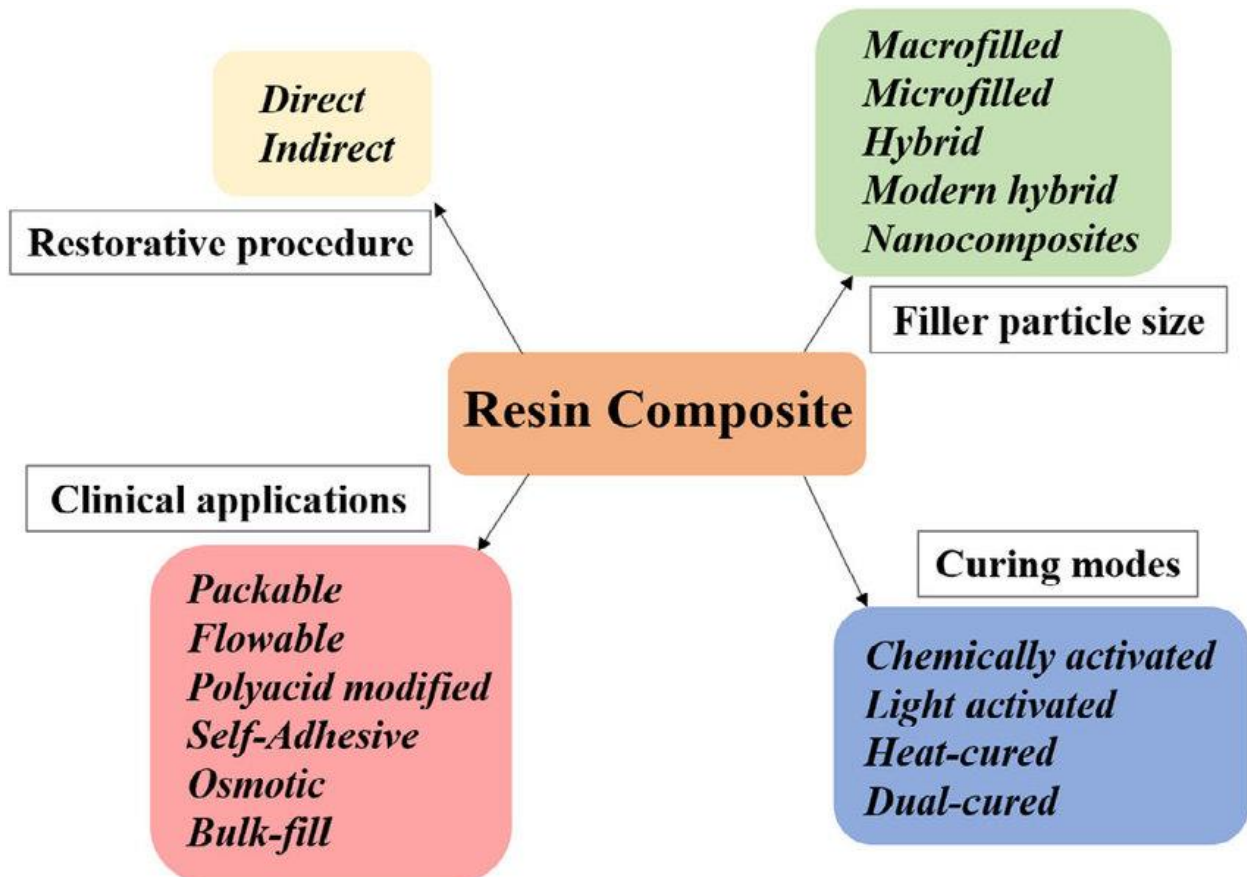
### Composite

A composite material is a combination of two materials with different physical and chemical properties. When they are combined they create a material which is specialized to do a certain job, for instance to become stronger, lighter or resistant to electricity. They can also improve strength and stiffness.

## Properties

Properties of composites are as diverse as the range of materials that fall within this broad classification. Under ideal conditions, the resultant properties of the composite are:

1. High strength/weight ratio.
2. Impact resistant.
3. Chemical/environmental stability.





## **Glass Ionomer Cement**

Glass ionomer cement (GIC) is a self-adhesive restorative material. Chemically, it combines fluoro-aluminosilicate glass powder and polyacrylic acid liquid. It has a broad spectrum of restorative and pediatric dentistry uses and exhibits a potent anti-cariogenic action.

### **Composition**

#### **Powder**

- Acid soluble calcium fluoroaluminosilicate glass.
- Silica - 41.9%
- Alumina - 28.6%
- Aluminum fluoride - 1.6%
- Calcium fluoride - 15.7%
- Sodium fluoride - 9.3%
- Aluminum phosphate - 3.8%
- Fluoride portion act as ceramic flux. Strontium,
- Barium or zinc oxide provide radio opacity.

#### **Liquid :-**

- 1. Polyacrylic acid in the form co-polymer with itaconic acid & malic acid
- 2. Tartaric acid: improves handling characteristic & increase working time.
- 3. Water: Medium of reaction & hydrates the reaction products

### **Indications**

#### **Restorative Material**

Thanks to its easy placement and better marginal adaptation, glass ionomer cement is popularly used in pediatric restorations. It is also indicated for restoring permanent teeth in low stress-bearing areas like class III and V lesions. It is the material of choice in high-caries-risk patients due to the fluoride release.

#### **Luting Agent**

GIC can be used for luting of indirect restorations (metal and metal-ceramic) post and core and orthodontic bands and brackets.



## **Pulp Protection**

GIC is used as a liner or base beneath metallic and composite restorations (sandwich technique).

## **Pit and Fissure Sealant**

GIC-based fissure sealants offer less retention than resin-based ones, only indicated as temporary sealants in newly erupted permanent teeth. The caries preventive action of GIC-based pit and fissure sealants is comparable to resin-based pit and fissure sealants.

## **A-traumatic Restorative Technique**

A-traumatic restorative technique (ART) is a minimally invasive procedure that involves removing carious tissue with hand instruments without anesthesia. Restoration of the cavity requires an adhesive material like glass ionomer cement (GIC). ART is performed in those cases where routine dental treatment cannot be done because of a lack of facilities or accessibility to the dental clinic.

## **Fluoride release**

Two mechanisms have been proposed to explain the fluoride release from GIC into an aqueous solution. The first mechanism is a short-term process involving rapidly dissolving fluorides from the outer surface into the solution. The second mechanism is a continuous and gradual diffusion of fluoride through the cement.

## **Anticariogenic action**

The anti-cariogenic action of fluoride can be explained by various mechanisms: decreased demineralization, increased remineralization, enhancing the resistance of enamel to acid attack by conversion of hydroxyapatite to fluoroapatite, and the inhibition of enolase enzyme, thus interrupting microbial replication and metabolism. A sustained fluoride release from the restoration in the marginal gaps (between restoration and tooth) helps prevent secondary caries. This property of GIC makes it the material of choice for restorations in patients with high caries activity.

## **Classification of GIC**

GIC is classified based on application as follows:

- **Type I** - Luting cement used for cementation of crowns and bridges
- **Type II** - Restorative cement used for aesthetic fillings
- **Type III** – GIC used as liners and bases

- **Type IV** – GIC used as pit and fissure sealants
- **Type V** – GIC used for orthodontic cementation
- **Type VI** – GIC is used for core build-up in highly mutilated teeth
- **Type VII** – Fluoride releasing light-cured GIC
- **Type VIII** – GIC for A-traumatic restorative treatment (ART)
- **Type IX** – GIC used for Pediatric and geriatric restorations

### **Advantages**

- Chemical bonding to the tooth structure
- Caries preventive action
- Thermal compatibility with tooth structure
- Mild pulp response
- Tooth-colored restorative material

### **Disadvantages**

- Poor mechanical properties, e.g., low compressive strength, low abrasion resistance, and fracture resistance, make its use restricted to low stress-bearing areas
- Poor esthetics due to lack of translucency
- Moisture sensitive while setting the mere presence of microorganisms, as in bacteremia, does not constitute a-septic.

## Chapter: 5

### Orthodontics

#### Definition:

Orthodontics is a dentistry specialty that addresses the diagnosis, prevention, management, and correction of mal-positioned teeth and jaws, as well as misaligned bite patterns. It may also address the modification of facial growth, known as dentofacial orthopedics.

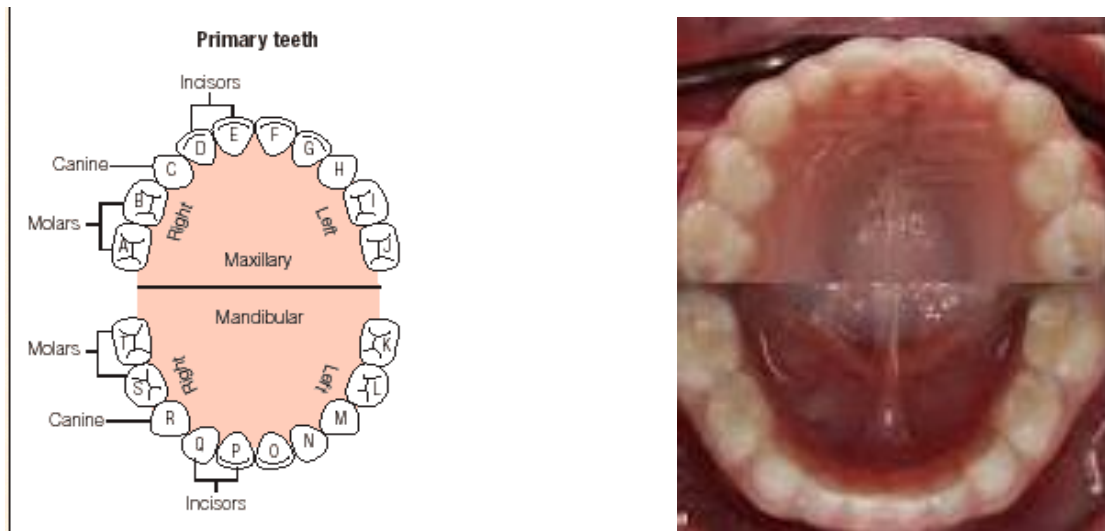
#### 5.1. Types of Dentition:

There are 3 types of dentition:

1. Primary (Deciduous) dentition
2. Mixed dentition
3. Permanent dentition

#### 1. Primary dentition

The primary dentition is developed during the period from 6-30 months and is later replaced by permanent teeth between 6-12 years of age. There are 20 teeth- ten in the maxilla and ten in mandible



**Figure:** Primary Dentition

### Sequence and age of eruption of primary (deciduous) teeth:

1. Mandibular central incisor – 6 months
2. Mandibular lateral incisor – 7 months
3. Maxillary central incisor – 7 1/2 months
4. Maxillary lateral incisor – 9 months
5. Mandibular 1st molar – 12 months
6. Maxillary first molar – 14 months
7. Mandibular canine – 16 months
8. Maxillary canine – 19 months
9. Mandibular second molar – 20 months
10. Maxillary second molar – 24 months

### 2) Mixed dentition:

Stage in which both primary and some permanent teeth are present. Mixed dentition stage extends from 6-12 years of age

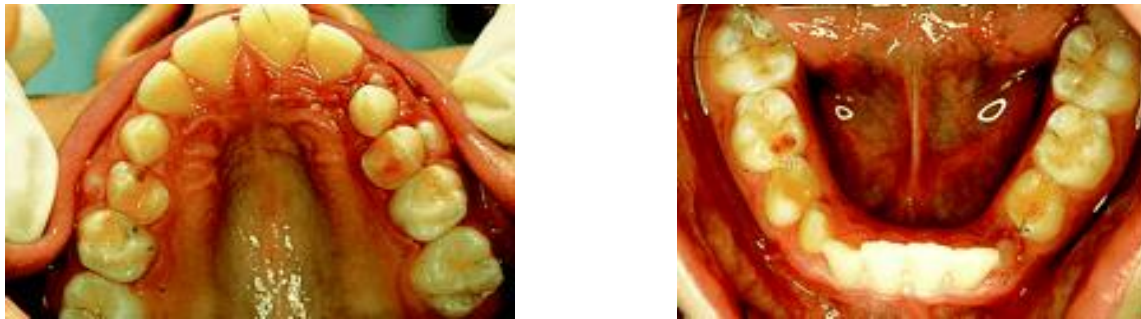

Figure: Mixed Dentition

### 3) Permanent dentition:

Stage in which only the permanent teeth are present in the arches. There are 32 teeth in permanent dentition

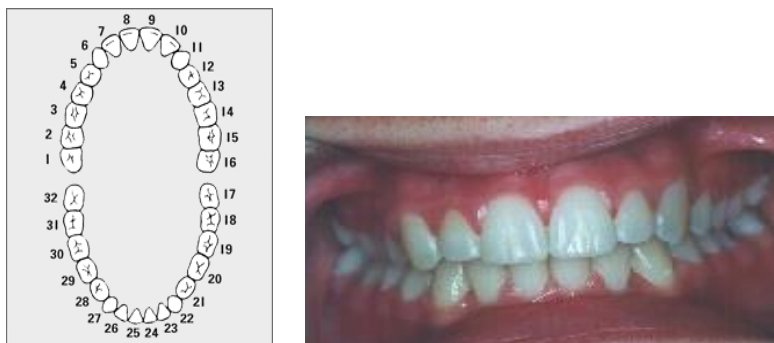

Figure: Permanent Dentition

### **Sequence and age of eruption of Permanent teeth:**

1. Mandibular first molar – 6-7 years
2. Maxillary first molar – 6-7 years
3. Mandibular central incisor – 6-7 years
4. Mandibular lateral incisor – 7-8 years
5. Maxillary central incisor – 7-8 years
6. Maxillary lateral incisor – 8-9 years
7. Mandibular canine – 9-10 years
8. Mandibular first premolar – 10-12 years
9. Maxillary first premolar – 10-12 years
10. Mandibular second premolar – 11-13 years
11. Maxillary second premolar – 11-13 years
12. Maxillary canine – 12-13 years
13. Mandibular second molar – 12-13 years
14. Maxillary second molar – 12-13 years
15. Mandibular third molar – 17-21 years
16. Maxillary third molar – 17-21 years

### **Occlusion:**

The relationship of maxillary and mandibular teeth when jaws are closed

### **Malocclusion:**

An occlusion that is beyond the accepted normal is known as Malocclusion

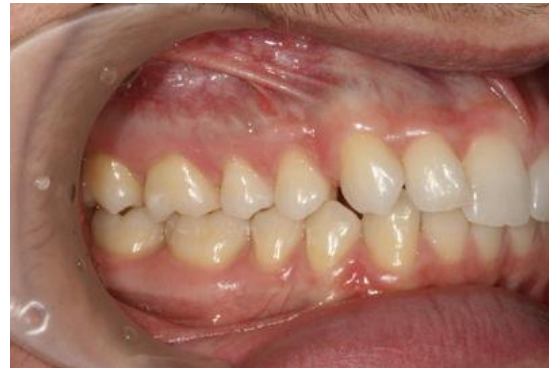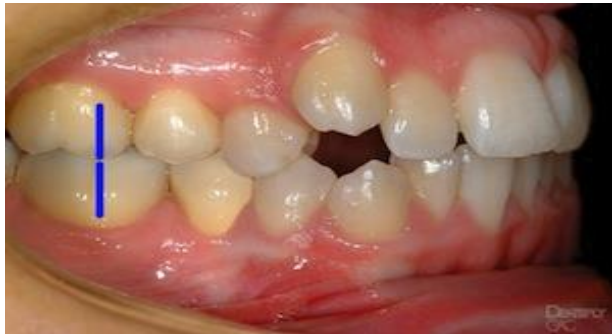### **5.2. Classification of Malocclusion:**

Most widely accepted system of classification of malocclusion used today was formulated by Edward H. Angle in 1898. According to this, the malocclusion is classified as:

- 1) Class I malocclusion (Neuroclulsion)
- 2) Class II malocclusion (Distoclusion)
- 3) Class III malocclusion (Mesioclulsion)

## 1. Class I malocclusion (Neuroclulsion):

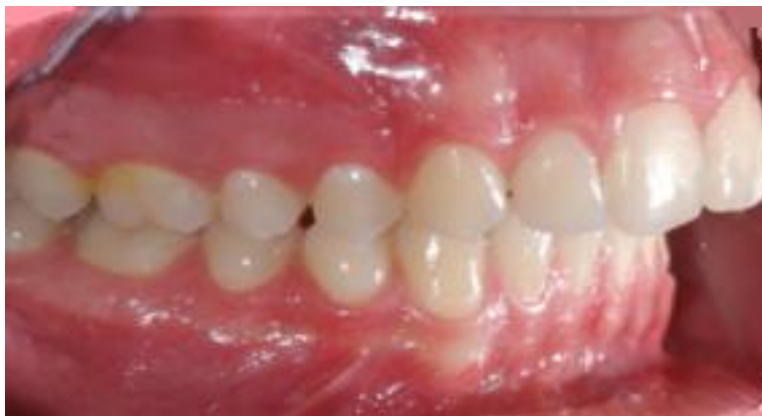When the molars are in class-I relation i.e. mesiobuccal cusp of upper 1<sup>st</sup> molar occludes in buccal groove of lower 1<sup>st</sup> molar, but some other irregularities exist. e.g. crowding, rotations etc.



**Figure:** Class-I malocclusion

## 2. Class II malocclusion (Distoclusion):

The mandibular first molar is in a distal relationship to the maxillary first molar. The mesiobuccal cusp of the maxillary 1<sup>st</sup> molar occludes in the embrasure formed by the lower second bicuspid and lower first molar



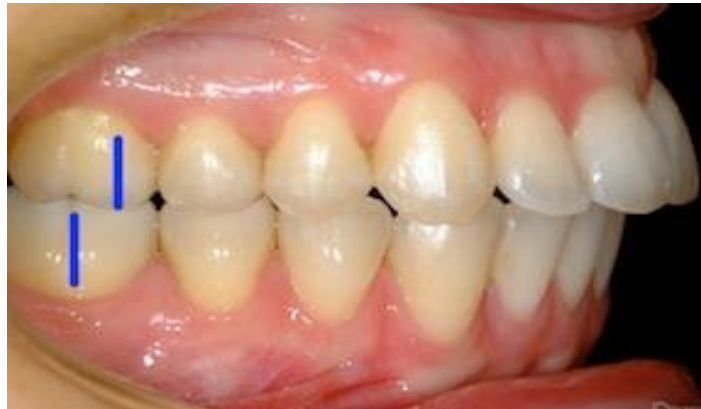**Figure:** Class II malocclusion

**Class II malocclusion has two divisions:**

- i) Class II division 1
- ii) Class II division 2

**i) Class II division 1:**

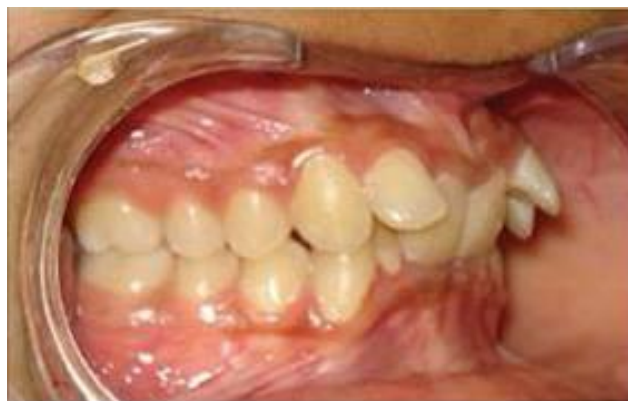Molars are in class II relation and maxillary incisors are proclined



**Figure:** Class II div 1 malocclusion

**ii) Class II division 2:**

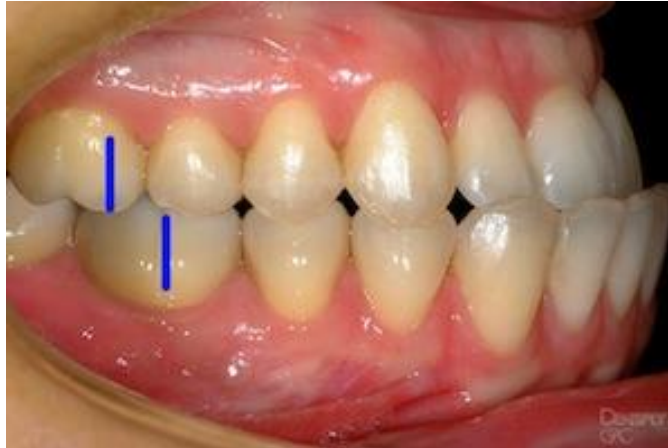Molar Class II relation and maxillary central incisors are retroclined while lateral incisors are proclined.



**Figure:** Class II div 2 malocclusion

### 3. Class III malocclusion (Mesioclusion):

Mandibular molars are positioned too far anterior (forward) in relation to the maxillary 1st molars. The mesiobuccal cusp of the maxillary 1st molar occludes with the distobuccal cusp of the mandibular 1st molar and mesiobuccal cusp of 2nd molar



**Figure:** Class III malocclusion

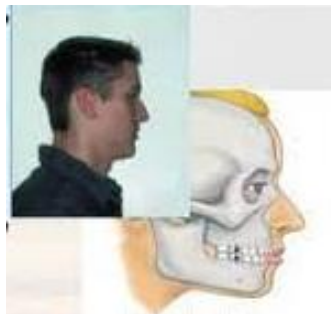
### Skeletal Classification of Malocclusion:

It considered relationship of Maxilla and Mandible in antero-posterior direction. There are 3 types of skeletal malocclusions:

1. Skeletal Class- I
2. Skeletal Class- II
3. Skeletal Class- III

#### 1. Skeletal Class- I:

Maxilla and mandible are in harmony with each other i.e. mandible is placed slightly behind the maxilla

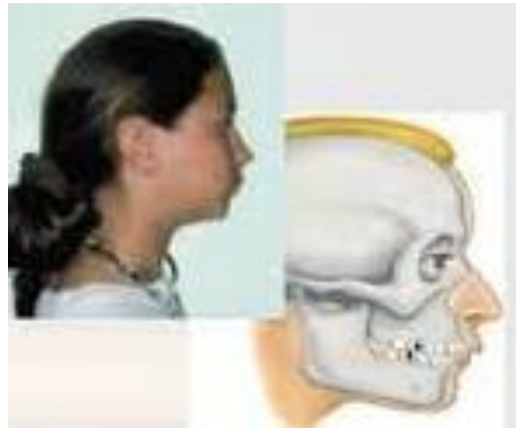

**Figure:** Skeletal Class- I facial profile



## 2. Skeletal Class- II:

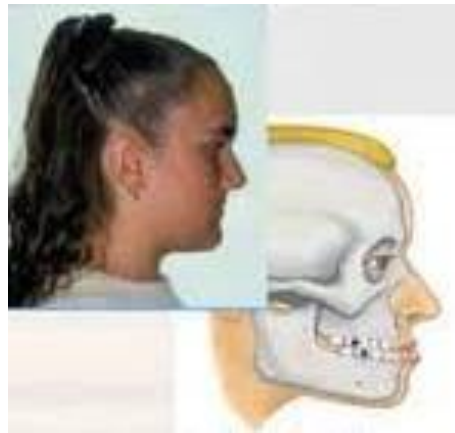Maxilla is placed ahead of the mandible or mandible is placed distal to maxilla



**Figure:** Skeletal Class- II facial profile

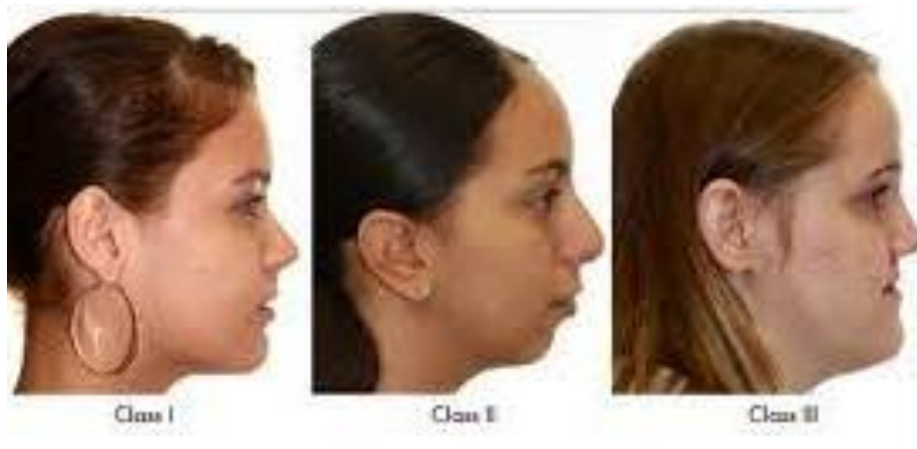## 3. Skeletal Class- III:

Maxilla is placed posterior to mandible or mandible is placed ahead of maxilla



**Figure:** Skeletal Class III facial profile

## Summary:



### 5.3. Orthodontic Appliances:

Devices which apply pressure to a tooth or group of teeth to move them in a predetermined directions

#### Types:

- I. Removable Orthodontic Appliances
- II. Fixed Orthodontic Appliances
- III. Functional Appliances

#### I. Removable Orthodontic Appliances

These are appliances that can be removed by the patient without any supervision by the orthodontist. It can also be taken out of the mouth for cleaning by the patient and for adjustment by the orthodontist. It apply their forces by means of springs, screws and bows of various types.

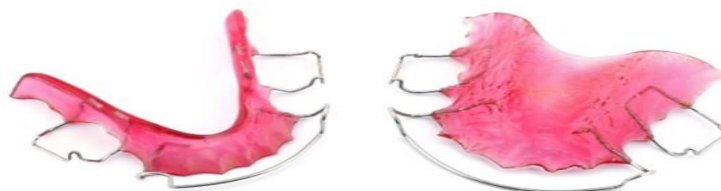

Figure: Removable Orthodontic appliances

**Indications:**

1. Limited (tipping) movements especially for correction of individual tooth movement
2. Arch expansion
3. Growth modification during the mixed dentition period
4. Retention after comprehensive orthodontic treatment

**Advantages:**

1. No hindrance to oral hygiene procedures
2. Cleaned by patient
3. Aesthetically pleasing
4. Less technique sensitive
5. Limited inventory
6. Bite planes can be incorporated
7. Economically Cheap
8. Easy fabrication
9. Less chair side time
10. No extensive training required

**Disadvantages:**

1. Patient cooperation
2. Limited tooth movement
3. Complex problems cannot be treated
4. Appliance loss/ breakage

**Components of Removable appliances:**

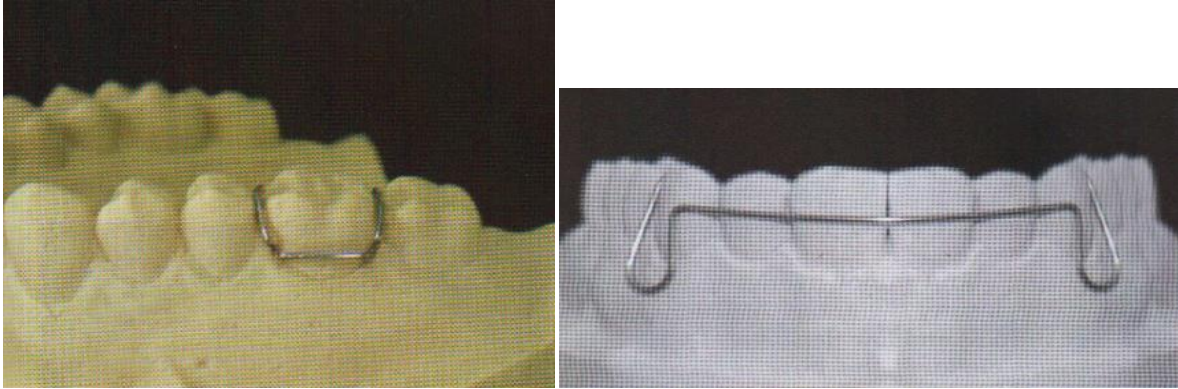
There are 3 basic components

1. Retentive components
2. Base plate or framework
3. Active components

**1. Retentive Components:**

These keep appliance in place and resist displacement of appliance

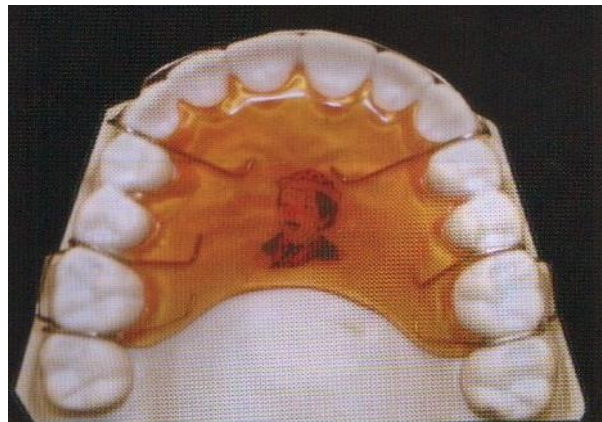
These include Clasps and Bows



**Figure:** Adams Clasp and Labial bow

## **2. Base Plate or Framework**

It unites all components of appliance, Anchor the appliance and support wire components



**Figure:** Base Plate or framework

## **3. Active Components:**

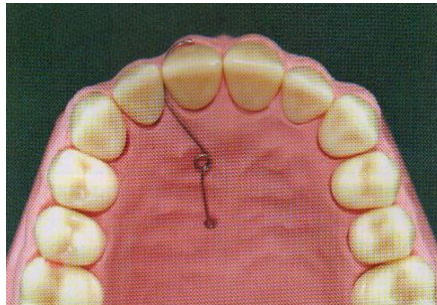
These make the tooth movements possible. These include:

Springs, Bows, screws etc

## Common types of springs:

### 1. Finger Spring

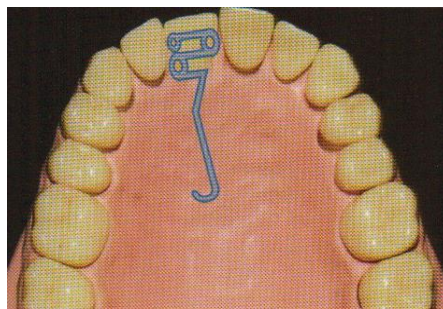
Applied for mesial and distal movement of teeth within the arch



**Figure:** Finger spring

### 2. Z spring:

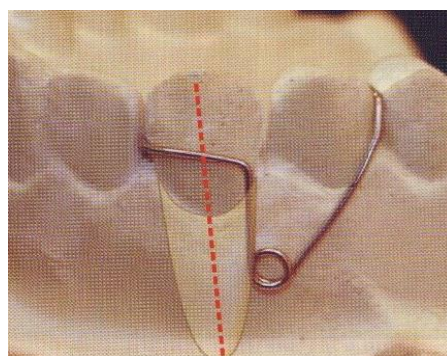
Applied for moving the teeth in labial direction



**Figure:** Z spring

### 3. Buccal Canine Retractor:

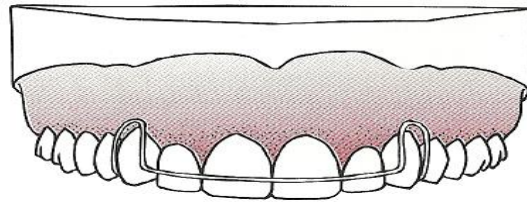
Applied for retraction of canines



**Figure:** Canine Retractor

### **Bows (labial Bow):**

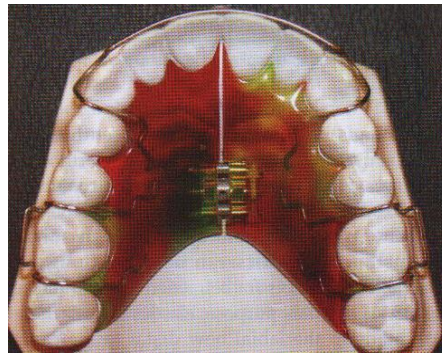
Used for lingual Tipping of proclined anterior teeth



**Figure:** Labial bow

### **Screws:**

Used for Expansion of arch.

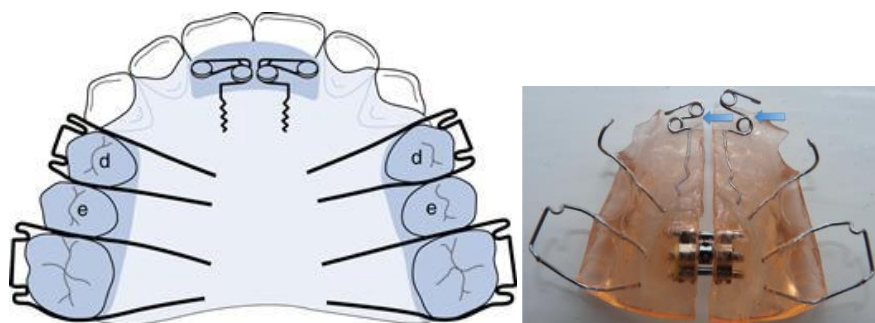


**Figure:** Expansion screw

### **Types of Removable Appliances**

#### **1. Conventional removable appliances:**

Used for simple movements of teeth by springs, bows etc or retention of corrected teeth. e.g. Hawley's appliances



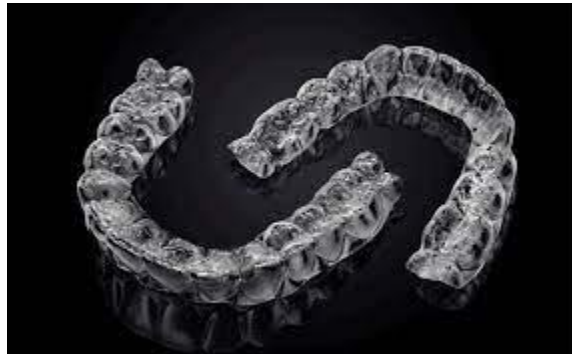**Figure:** Conventional removable appliances



## 2. Removable functional jaw orthopedic appliances:

These are used for growth modification of jaws. E.g. Bionator, Twin block, Face mask

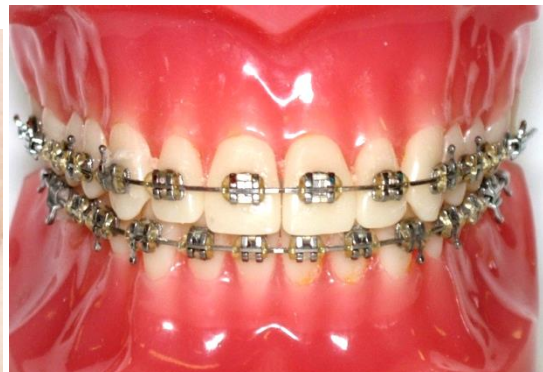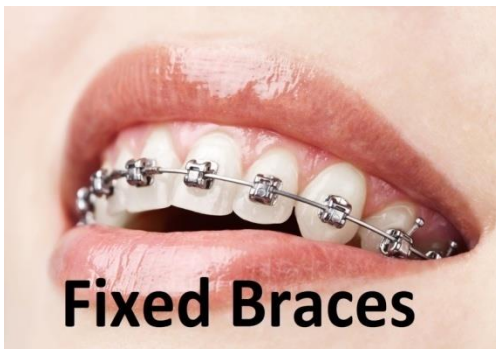## 3. Clear Aligner appliances:



**Figure:** Clear Aligners

## II. Fixed Orthodontic Appliances:

- These are orthodontic devices, which have attachments that are fixed onto the tooth surface, and forces are exerted on tooth via attachments using arch wires and other auxiliaries.
- These appliances cannot be removed or activated by patient.



**Figure:** Fixed Orthodontic appliances

### Indications:

1. Multiple tooth movements at the same time in the arch
2. Root movement (torque)

3. Correction of rotations
4. Intrusion / extrusion of teeth
5. Tipping / bodily movements of teeth

**Advantages:**

1. Multiple tooth movements can be made at once
2. Precise tooth control possible

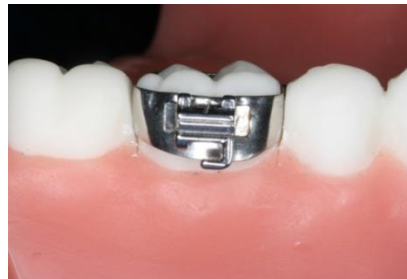**Disadvantages:**

1. Aesthetics
2. Difficulty in oral hygiene maintenance
3. Anchorage control / treatment monitoring more difficult
4. Expensive

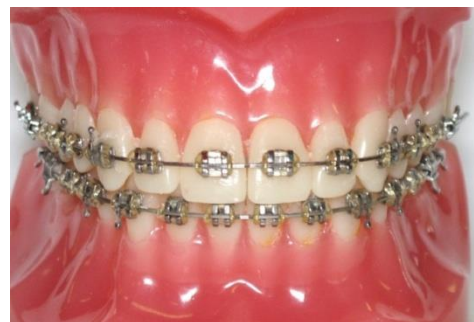**Components of Fixed Orthodontic appliances:**

**1) Attachments**

- **Bands**

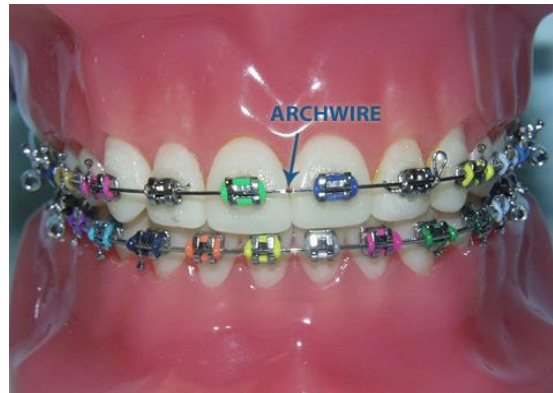

- **Brackets**

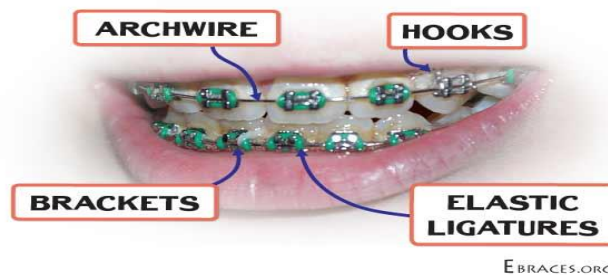
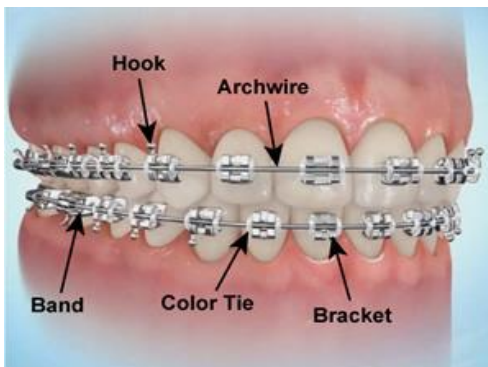




## 2) Archwires



## 3) Auxilliaries

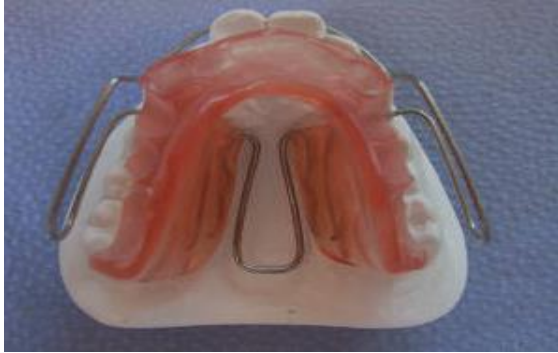

## III. Functional Appliances:

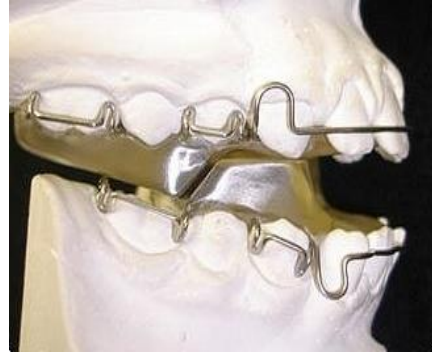
These are used for growth modification. In other words they are used for the correction of skeletal malocclusion by dentofacial orthopedics. e.g. Bionator, Twin block, Face mask etc.

- a) Bionator
- b) Twin Block

Both of above appliances are used for correction of Skeletal Class II malocclusion due to short mandible (growth enhancement of mandible)



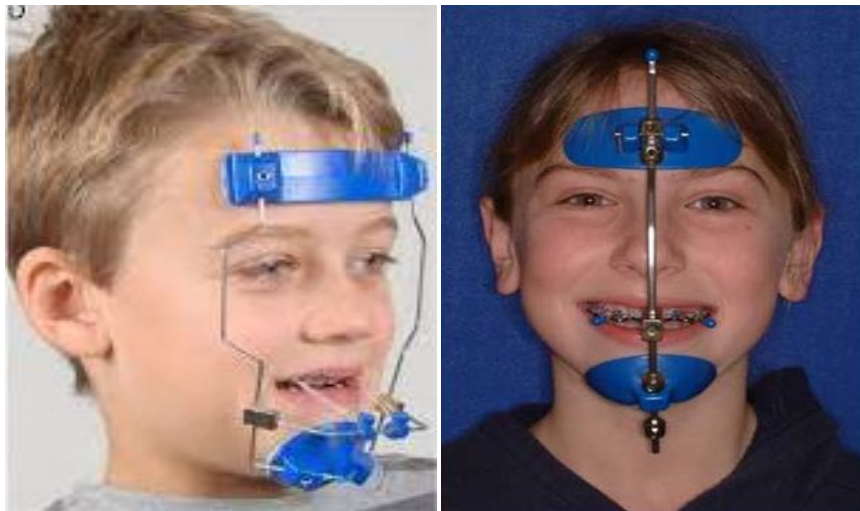
**Figure:** Bionator



**Figure:** Twin Block

c) Face Msk:

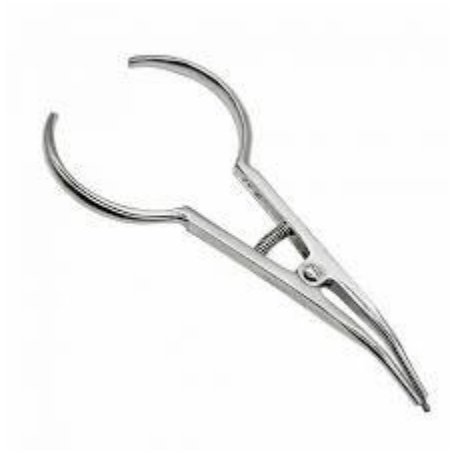Used for treatment of Class-III malocclusion (growth enhancement of Maxilla)



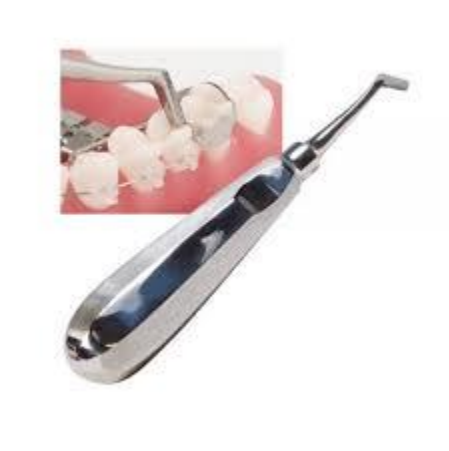**Figure:** Face Mask

#### 5.4. Common Instruments Used in Orthodontics:

1. Separator placing pliers



2. Band pusher



3. Band removing pliers



#### 4. Mathieu pliers



#### 5. Weingarten pliers



## Chapter: 6

### Local Anesthesia

#### Definition:

Local anesthesia is any technique to induce the absence of sensation in a specific part of the body, using a type of medicine called a local anesthetic.

#### 6.1. Common Local Anesthetic Solutions in dentistry:

**Lignocaine:** hydrochloride is effectively absorbed from mucous membranes and is a useful surface anesthetic in concentrations up to 10%

**Procaine:** is a short-acting local anesthetic. It is used for reducing painful symptoms of various types, and it is widely used in infiltration, block, epidural, and spinal cord anesthesia, and for potentiating activity of basic drugs during general anesthesia.

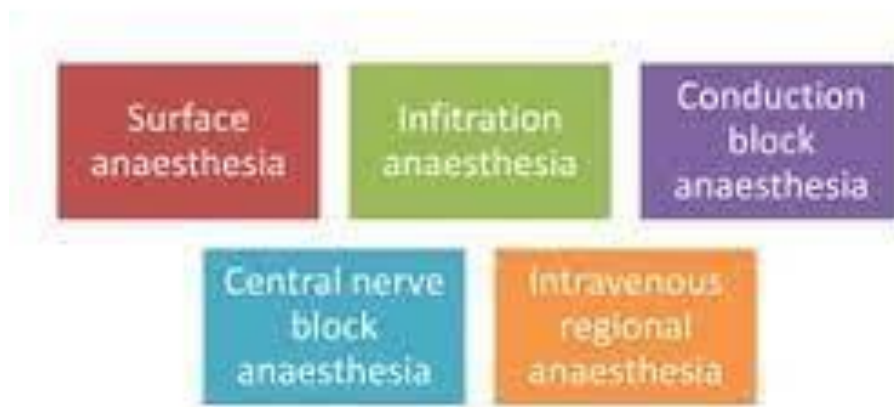**Bupivacaine:** is a potent local anesthetic used in regional anesthesia, epidural anesthesia, spinal anesthesia, and local infiltration.

#### 6.2. Ideal Properties of local anesthesia:

1. Reversible action
2. Non-irritant
3. No allergic reaction
4. No systemic toxicity
5. Rapid onset of action
6. Sufficient duration of action
7. Potent
8. Stable in solutions
9. Not interfere in healing of tissues
10. Have a vasoconstrictor action
11. Not expensive

### 6.3. Types of Local Anesthetic:

#### Types of local anesthetic



### 6.4. Types of Nerve anesthesia in Dentistry:

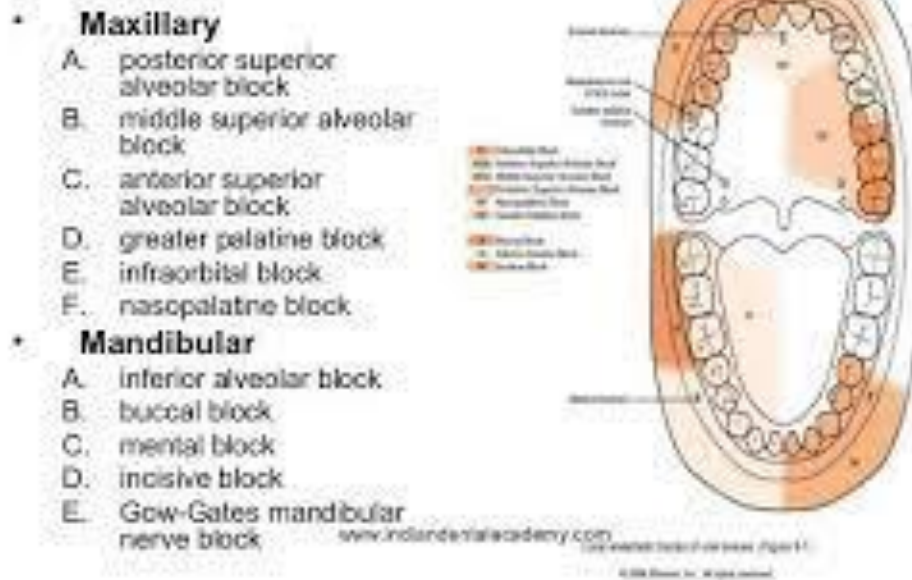
#### Maxilla:

- c) Posterior Superior Alveolar Block
- d) Middle superior alveolar block
- e) Anterior superior alveolar block
- f) Greater palatine block
- g) Infraorbital block
- h) Nasopalatine block

#### Mandible:

- a) Inferior alveolar block
- b) Buccal block
- c) Mental block
- d) Incisive block
- e) Gow-Gates mandibular nerve block

## Types of Nerve Anesthesia



**Figure:** Types of Nerve Anesthesia

### 6.5. Composition of Local anesthetic solution:

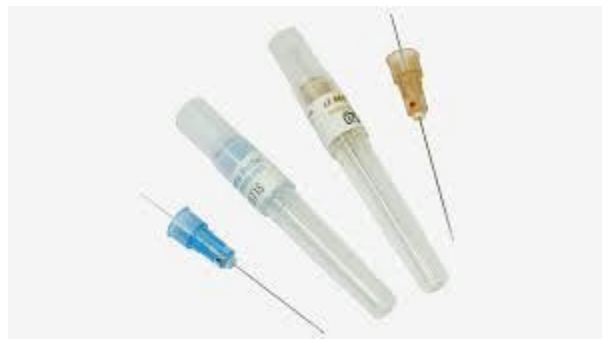1. Local anesthetic agent: Lignocaine Hydrochloride (2%-20mg)
2. Reducing agent: Sodium meta-bisulphite (0.5 mg)
3. Preservative: Methylparaben (0.1%-1mg)
4. diluting agent: Distilled water
5. Fungicide: Thymol
6. Isotonic Solution: Sodium chloride or Ringer's solution (6mg)
7. Vasoconstrictor: Adrenaline (1:80,000-0.012mg)
8. To adjust pH of solution: Sodium Hydroxide
9. Nitrogen bubble: to prevent oxygen from being trapped in the cartridge and potentially destroying the vassopressor

## 6.6. Equipment required for Local anesthesia:

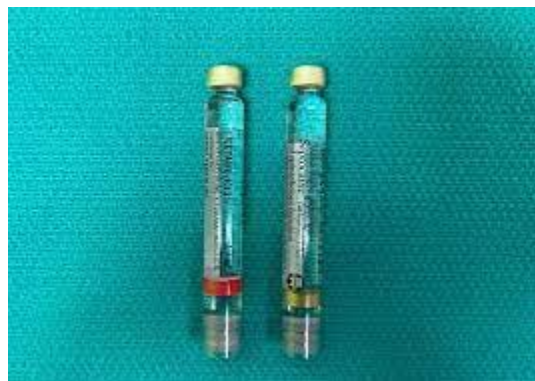### 1. Dental Syringe



### 2. Dental Needle

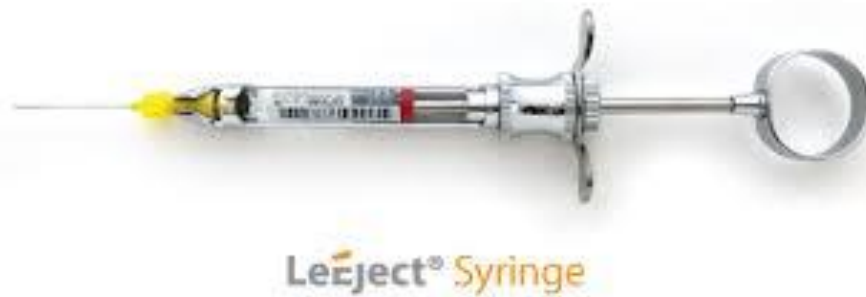

### 3. Cartridge





## Assembled form

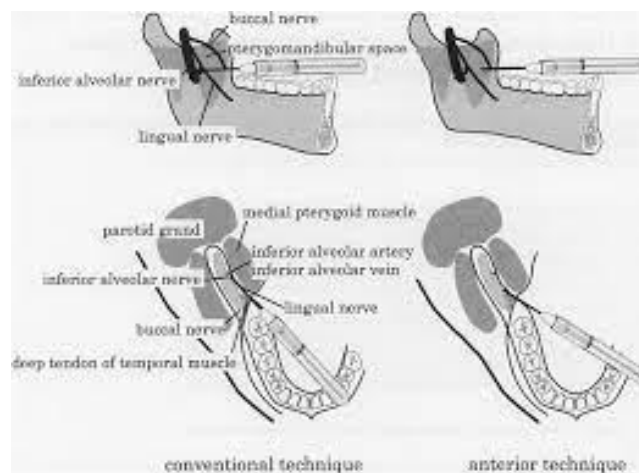


### 5.7. What is Infiltration Nerve Block?

Infiltration anesthesia is often used for minor surgical and dental procedures. Nerve block anesthesia is used for surgical, dental, and diagnostic procedures and for pain management. [4, 5] Uses for infiltrative anesthetics are as follows: Subcutaneous infiltration (IV placement, superficial/shave biopsy, suturing).

#### How to administer Inferior alveolar nerve Infiltration block:

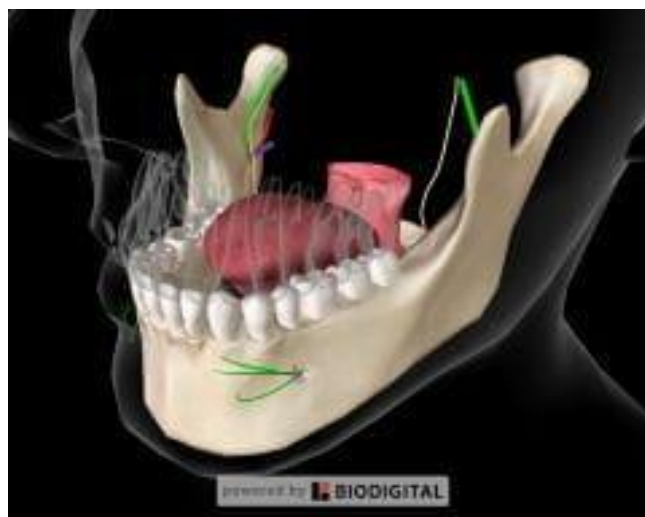
##### Relevant anatomy:



- The inferior alveolar nerve is a branch of the mandibular nerve, which is the 3rd branch of the trigeminal nerve.
- The inferior alveolar nerve travels inferiorly and anteriorly on the medial side of the mandibular ramus. The nerve, accompanied by the inferior alveolar artery and vein, enters the mandibular foramen near the midpoint of the ramus. From

this point, the nerve runs within and innervates the body of the mandible; a terminal branch, the mental nerve, reemerges through the mental foramen in the premolar region to innervate the lower lip and chin, as well as the lateral mucosa/gingiva overlying the lower incisor teeth, canine, and first premolar. After this branching, the inferior alveolar nerve continues anteriorly as the incisive nerve, to innervate the remaining teeth and bone anterior to the mental foramen up to the midline.

- The lingula is the bony protuberance at the anterior margin of the mandibular foramen.
- The coronoid notch (retromolar fossa) is the concavity of the anterior edge of the ramus, located posterior to the molars.
- The pterygomandibular triangle is a fatty space bordered laterally by the coronoid notch, and medially by the pterygomandibular raphe.
- The pterygomandibular raphe is a thin vertical band (a visible tendinous line where the buccinator and the superior pharyngeal constrictor muscles join) that borders the pterygomandibular triangle medially.
- The needle is inserted posterolaterally into the pterygomandibular triangle, parallel to and about 1 cm above the mandibular occlusal plane. The needle will encounter resistance as it passes through muscle and connective tissue.
- The anesthetic is ideally placed superiorly and posteriorly adjacent to the lingula (ie, just above the mandibular foramen).
- The lingual nerve (also a branch of the mandibular nerve) runs near the injection zone and is typically anesthetized incidentally to the inferior alveolar nerve block.



**Figure: Inferior Alveolar Nerve**

### **Positioning of Patient:**

- Position the patient slightly inclined (semi-recumbent sitting position), with the occiput supported and the mouth opened wide, such that the injection site (medial side of the ramus) is accessible.
- Right-handed operators should stand on the patient's right and left-handed operators on the patient's left.

### **Step by step description of the procedure:**

- Wear nonsterile gloves and a mask and safety glasses, or a face shield.
- Use gauze to thoroughly dry the pterygomandibular triangle. Use suction as needed to keep the area dry.
- Apply a small amount of topical anesthetic with cotton-tipped applicators and wait 2 to 3 minutes for the anesthesia to occur.

### **Inject the local anesthetic**

- Instruct the patient to open the mouth comfortably wide.
- Place the tip of your thumb or forefinger into the coronoid notch, to help visualize the vertical height at which the needle will enter, and retract the cheek to expose the pterygomandibular triangle.
- Place and maintain the barrel of the syringe over the contralateral lower 1st and 2nd premolars.
- Keep the needle parallel to—and about 1 cm above—the mandibular occlusal plane, at the vertical plane of the coronoid notch.
- To establish the correct angle of approach and entry point, rest the side of the needle tip against the lateral edge of the pterygomandibular raphe, such that the tip now aims into the pterygomandibular triangle, with the bevel facing the ramus. Maintain this angle of insertion as you advance the needle.
- Advance the needle tip slightly into the mucosa. Aspirate, to rule out intravascular placement, and inject a few drops of anesthetic to relieve the pain of the needle insertion itself. Repeat these small injections after incremental advancements of slightly < 1 cm.

**If the patient experiences a sudden, sharp paresthesia**, reassure the patient that means the needle is in the right spot. Slightly withdrawing and then redirecting the needle may relieve this sensation, but maintain direction toward the medial ramus and mandibular foramen.

- Advance the needle until it is stopped by the ramus (typically after about 2 to 2.5 cm of insertion) and withdraw needle 1 mm away from bone.

**If the needle does not hit mandibular bone**, it may be too far posterior (eg, into the parotid). Withdraw the needle and redirect it (more anteriorly/laterally).

- Once contact with the ramus is made, withdraw the needle 1 mm away from the bone.
- Aspirate, to rule out intravascular placement.
- **If aspiration reveals intravascular placement**, withdraw the needle 2 to 3 mm, then re-aspirate prior to injection.
- Slowly inject about 2 to 4 mL anesthetic, but leave about 0.5 mL in the syringe to block the buccal nerve.

### **Block the buccal nerve**

- Withdraw the syringe and reinsert it just anterior and lateral to the anterior edge of the ramus at the level of the occlusal surface of the most posterior molar. Advance the needle posteriorly about 3 to 5 mm. Aspirate, to rule out intravascular placement, and inject about 0.25 mL of anesthetic.
- Massage the injection sites to hasten the onset of anesthesia.

### **5.8. Complications:**

1. Allergic reaction to the anesthetic
2. Toxicity due to anesthetic overdose (eg, seizure, cardiac arrhythmias)
3. Intravascular injection of anesthetic/epinephrine
4. Hematoma
5. Neuropathy
6. Spread of infection, by passing the needle through an infected area
7. Anesthetization of branches of facial nerve (cranial nerve VII) due to excessively posterior needle placement
8. Failure to anesthetize
9. Needle breakage and loss of needle within soft tissues

Most complications result from inaccurate needle placement.

**Sample Questions:**

**Q.1:**

- a) What are dental caries?
- b) Write down the J.V Black classification of dental caries.

**Q.2:**

- a) What is gingivitis?
- b) Give a brief account of types of Gingivitis.

**Q.3:**

- a) Classify Dental Materials.
- b) Write the properties of Glass Ionomer cement.

**Q.4.** What are the advantages and disadvantages of Fix Orthodontic appliances?

**Q.5.** Write down the composition of Local Anesthetic solution

## **Reading Resources**

1. Ten Cates Oral Histology, Development, Structure and Function Antonio Nanci
2. Concise Dental Anatomy and Morphology by James L. Fuller, Gerald E Denehy, Thomas M. Schulein
3. Philips' Science of Dental Materials by Chiayi Shen,H.Ralph Rawls
4. McCracken's Removable Partial Prosthodontics by Alan B. Carr, Glen P. McGivney, David T.Brown
5. Prosthodontic Treatment for Edentulous Patients by George Alben Zarb, Carl Boucher
6. Planning and Making Crowns and Bridges by Bernard G. N. Smith, Leslie C. Howe.
7. Removable Orthodontic Appliances by Issacson
8. Fixed Orthodontic Appliances by Issacson
9. Functional Appliances by Issacson
10. Local Anesthesia in Dentistry by Jaques A.Baart
11. Online Resources